

# Facetten - Nervenwurzelblockade ISG - Caudalblockade und Radiofrequenz Kniegelenk

Univ. Prof. Dr. Rudolf Likar, MSc

Vorstand der Abteilung für Anästhesiologie,  
allgemeine Intensivmedizin, Notfallmedizin,  
interdisziplinäre Schmerztherapie und Palliativmedizin  
Klinikum Klagenfurt am Wörthersee  
LKH Wolfsberg

Lehrabteilung der Medizinischen Universität  
Graz, Innsbruck, Wien

Lehrstuhl für Palliativmedizin SFU



# KABEG

KLINIKUM KLAGENFURT  
AM WÖRTHERRSEE

# ZISOP

## Zentrum für interdisziplinäre Schmerztherapie (Onkologie) Palliativmedizin (Ambulanzen plus Bettenstation).

### Ambulanzen:

Interdisziplinäre Schmerzambulanz

Palliativambulanz

Interdisziplinäre onkologische Ambulanz

### **Palliativstation**

**Interdisziplinäre onkologische Station**

**Interdisziplinäre Schmerz Tagesklinik**

**Multimodale Therapiekonzept**

**Interdisziplinäre Station für Schmerzpatienten mit Nicht-Tumorerkrankungen**

### Abteilungen:

**Anästhesie**

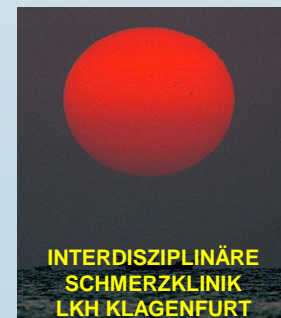**Neurologie** (Diagnostik, Therapie)

**Neurochirurgie** (*operativ, SCS und Schmerzpumpen*)

**Klinische Psychologie**

**Orthopädie**

**Radiologie**



**Jahr****2001****2002****2004****2007****2015****Patienten ambulant****804****1.396****1.750****2.150****2.950****Folgeuntersuchungen eines ambulanten Patienten****4.047****6.688****5.927****6.630****5.423****Konsiliartätigkeit bei stationären Patienten****6.490****6.455****7.019****9.190****6.424****2001: insgesamt 19.074 Leistungen****2002: insgesamt 21.895 Leistungen****2004: insgesamt 21.562 Leistungen****2007: insgesamt 22.323 Leistungen****2015: insgesamt 22.973 Leistungen**

## Blockaden CT-gezielt:

**424 / 2001**

**600 / 2002**

**964 / 2004**

**982 / 2007**

**995 / 2015**

## Invasive Verfahren

**1.284 / 2001**

**1.621 / 2002**

**1.950 / 2004**

**2.037 / 2007**

**2.150 / 2015**

*(Tageschirurgische Eingriffe)*

**25 bis 30 SCS (114.000 LKF-Punkte)**

**10 bis 15 Schmerzpumpen (220.000 LKF-Punkte)**

**Stationäre Aufnahme – Neurochirurgie, Neurologie, Orthopädie und andere Stationen).**

# Wie stellt man die Diagnose von Facettengelenksschmerzen?

- Manualmedizinische Diagnose:  
Sensitivität 89%, Spezifität 47%, LR 1.7

*King et al, Spine J 2007*

- Konventionelles Rx, CT, MRI:  
Keine Korrelation mit Schmerzen

*Bogduk & Lord, Neurosurg Quarterly 1998*

# Low back pain

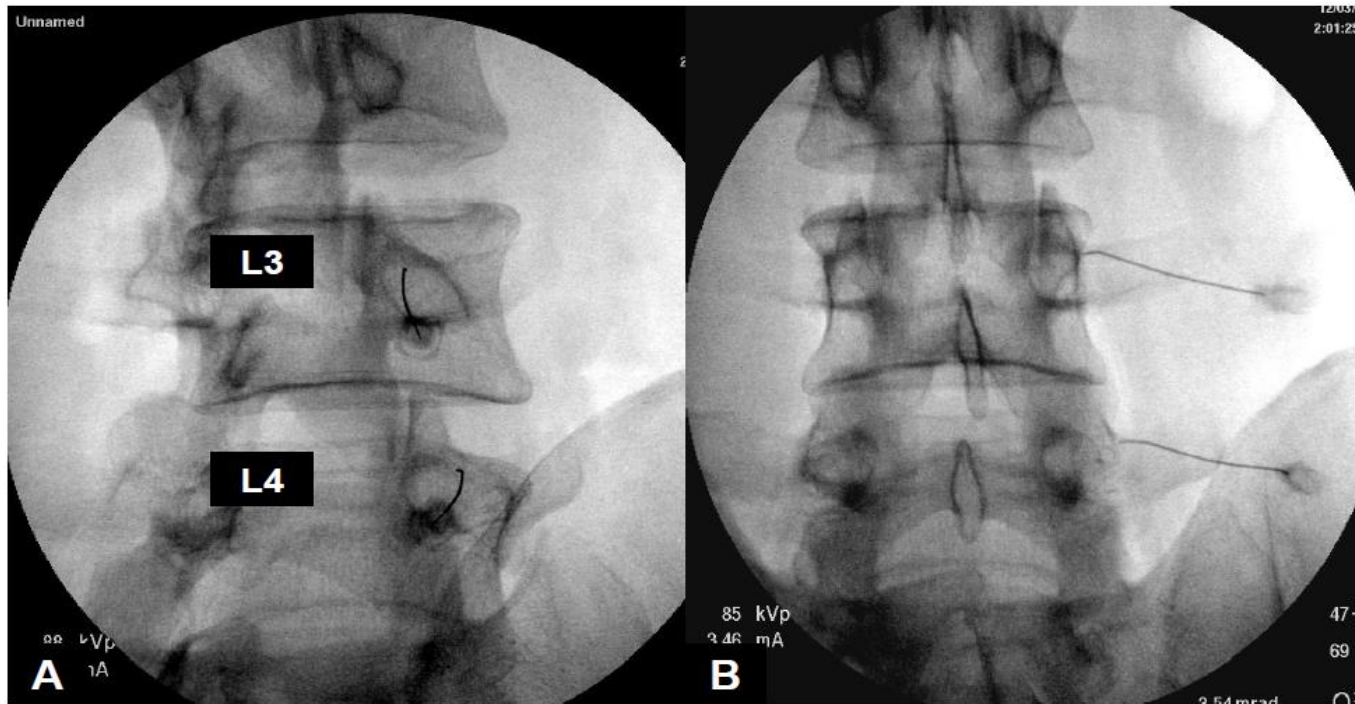
## Facettensyndrom

- **Diffuse Rückenschmerzen durch Bewegung verstärkt, ausstrahlend zum Beckenkamm und zur Leiste, Gesäß, Oberschenkel**
- **Blockierung und Fehlbelastung der kleinen Wirbelgelenke**
- **pseudoradikulär**

# Low back pain

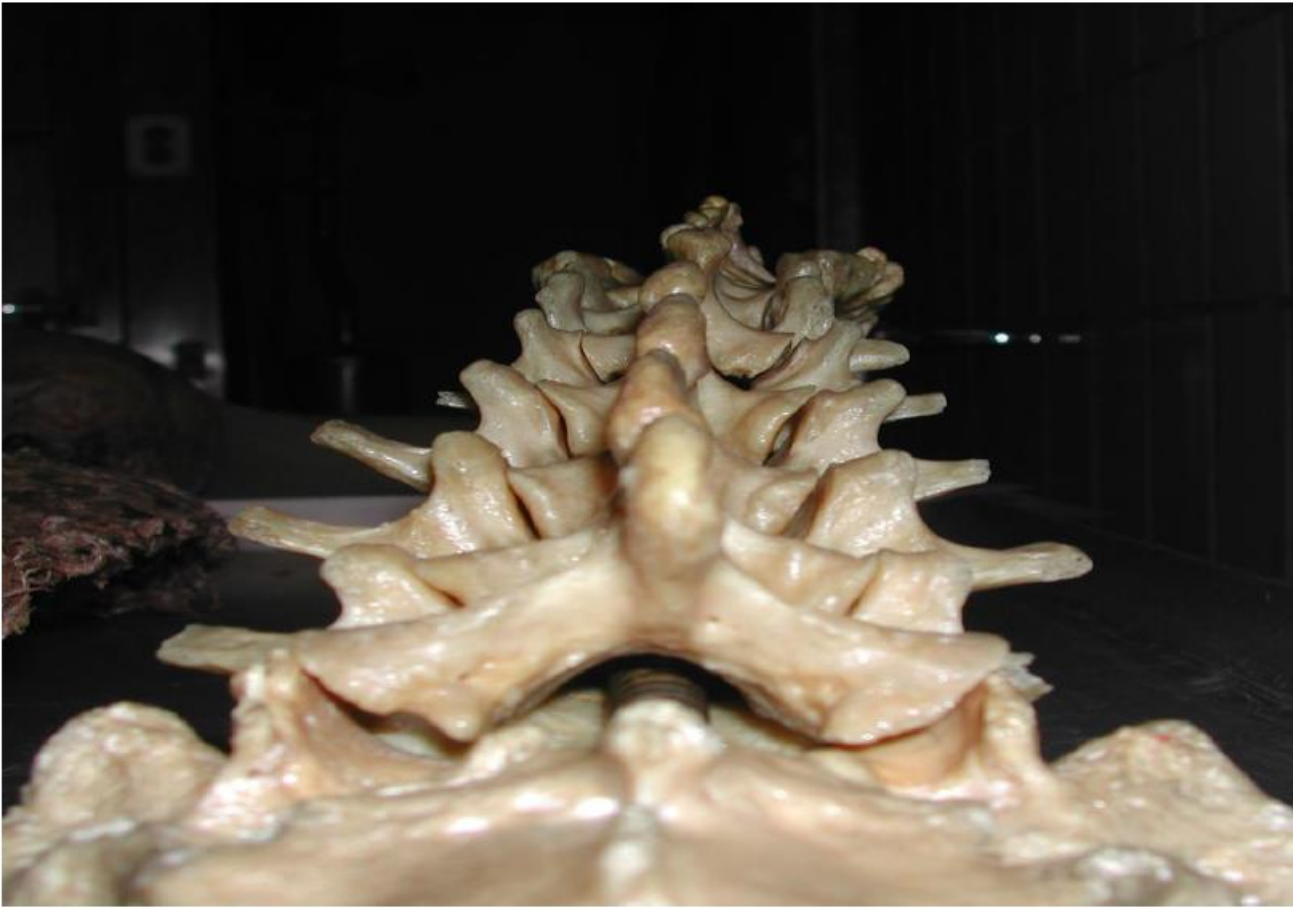## Indikationen zur Facettenblockade oder Facettendeneravierung

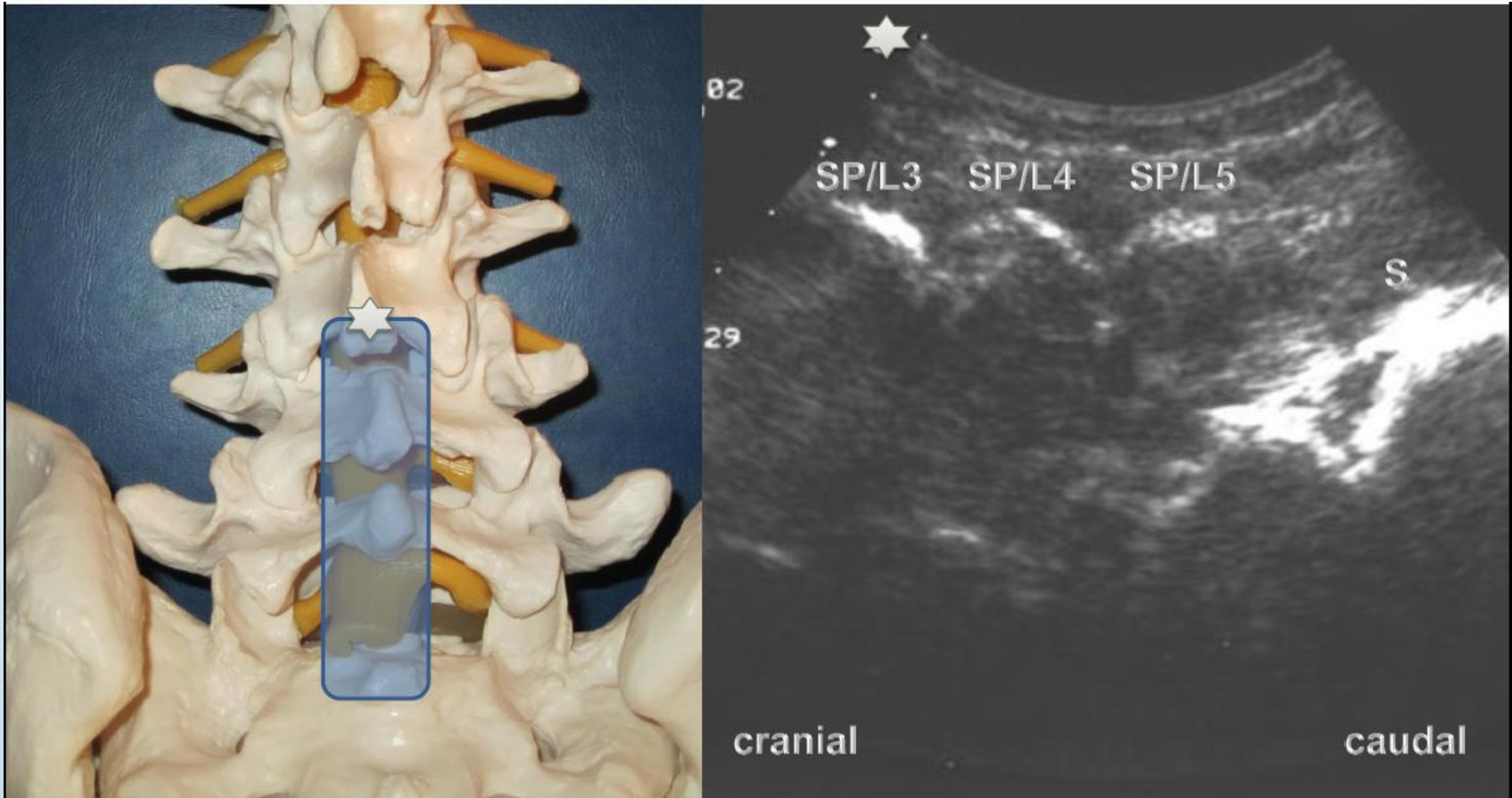
- **Pseudoradikulärer Schmerz in HWS, BWS, LWS**
- **Blockierung und Fehlbelastung der kleinen Wirbelgelenke**
- **Degenerative Veränderungen der Facettengelenke**
- **Addition zur periradikulären Therapie**

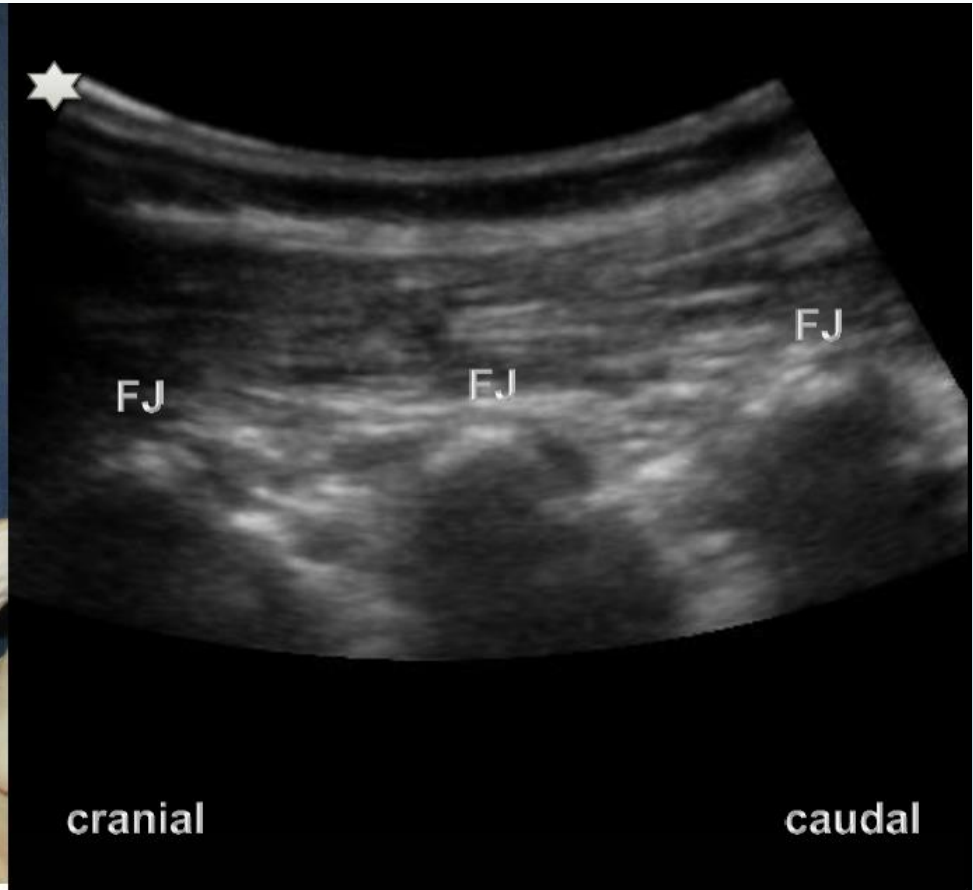
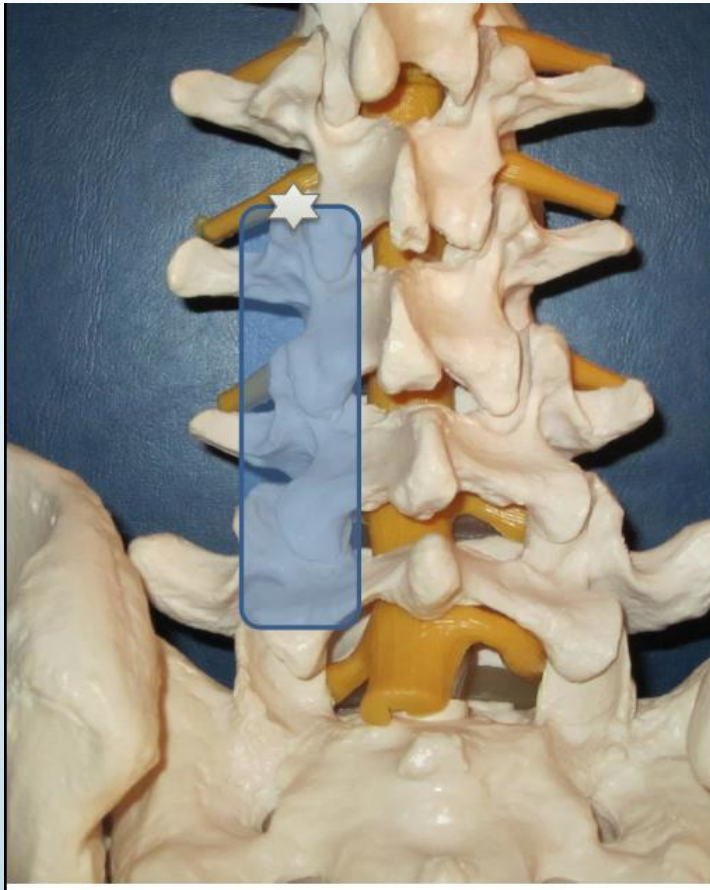

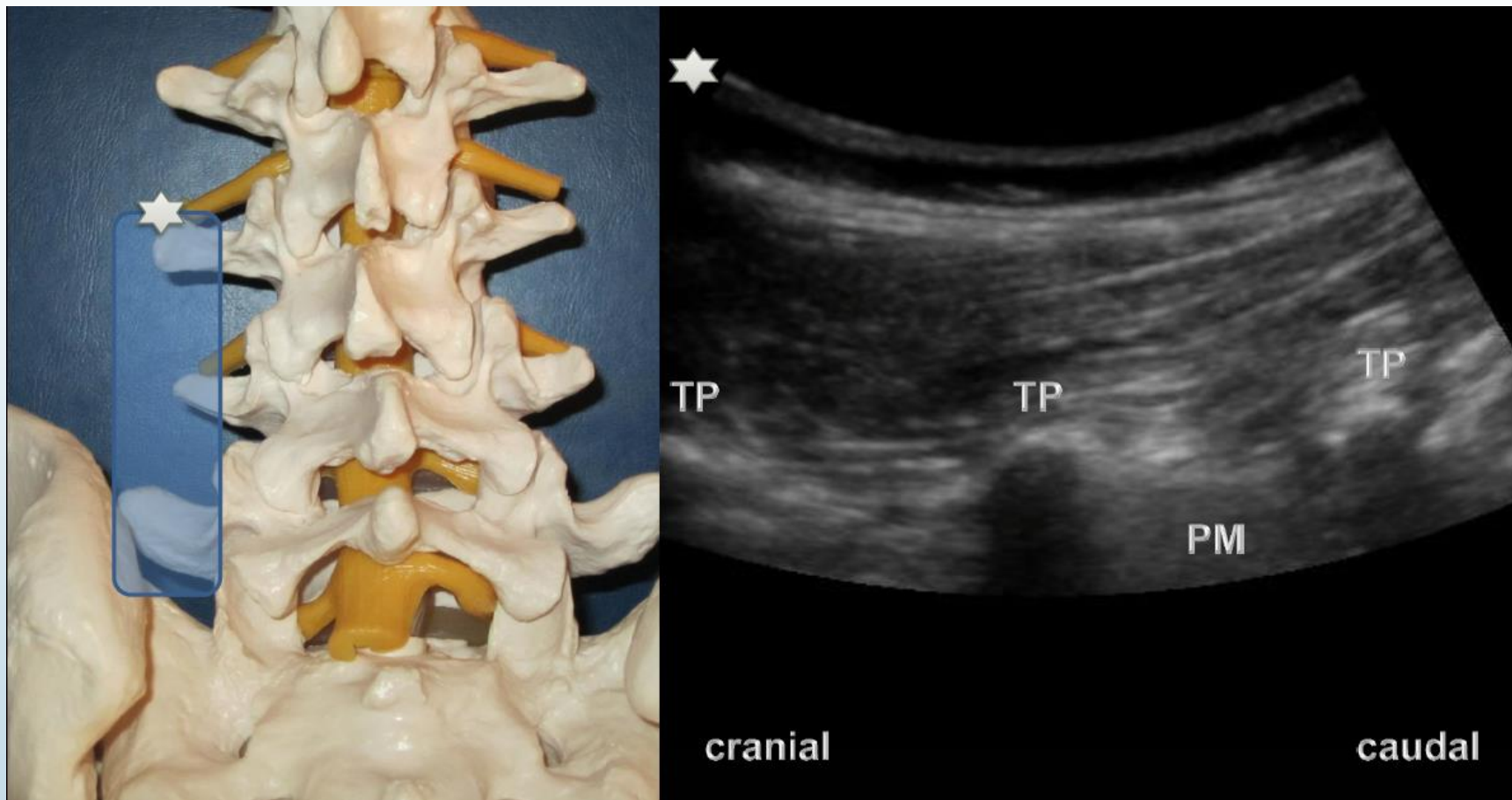


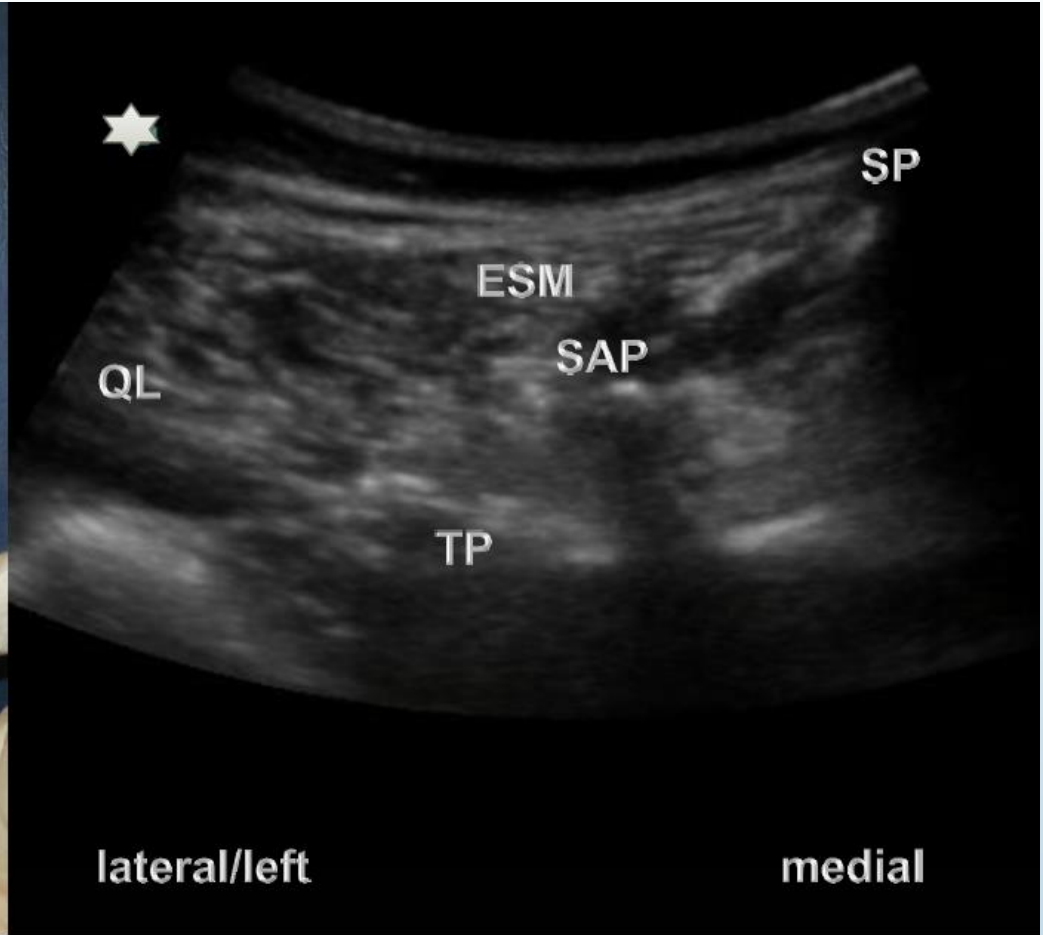
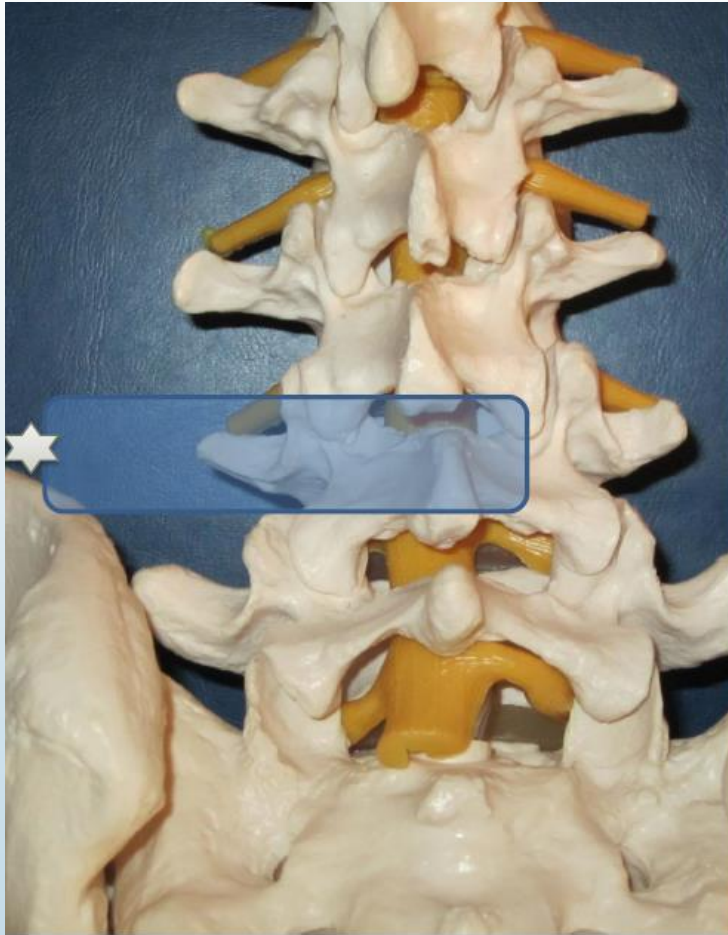
# Lumbar paravertebral region

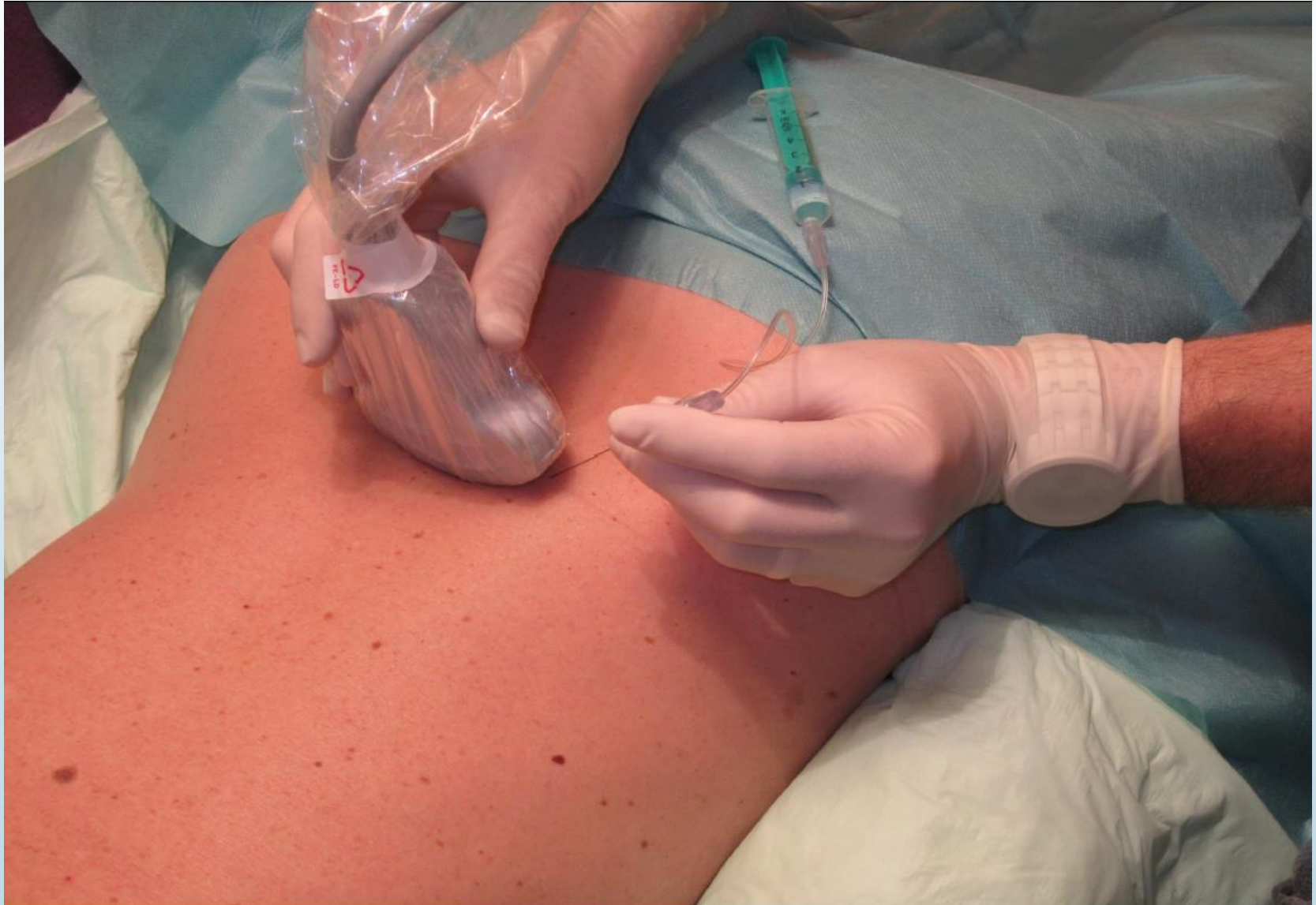

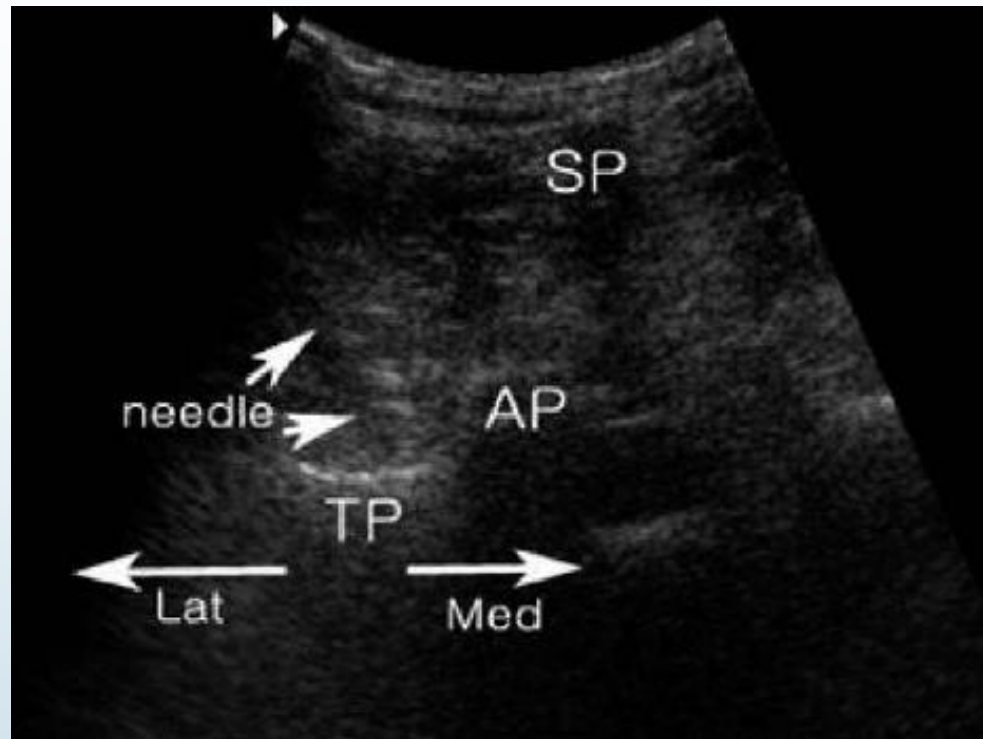






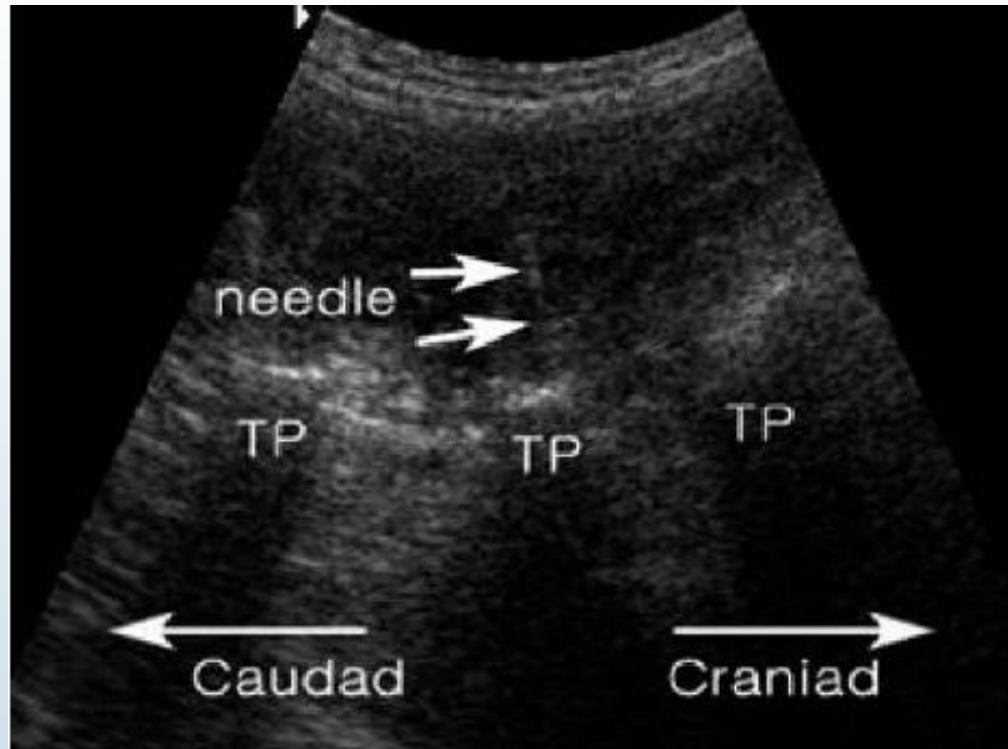






Ultrasonographic cross-axis view with the needle at the groove of the transverse process adjacent to the superior articular process. SP, spinous process; TP, transverse process; AP, articular process; Lat, lateral; Med, medial

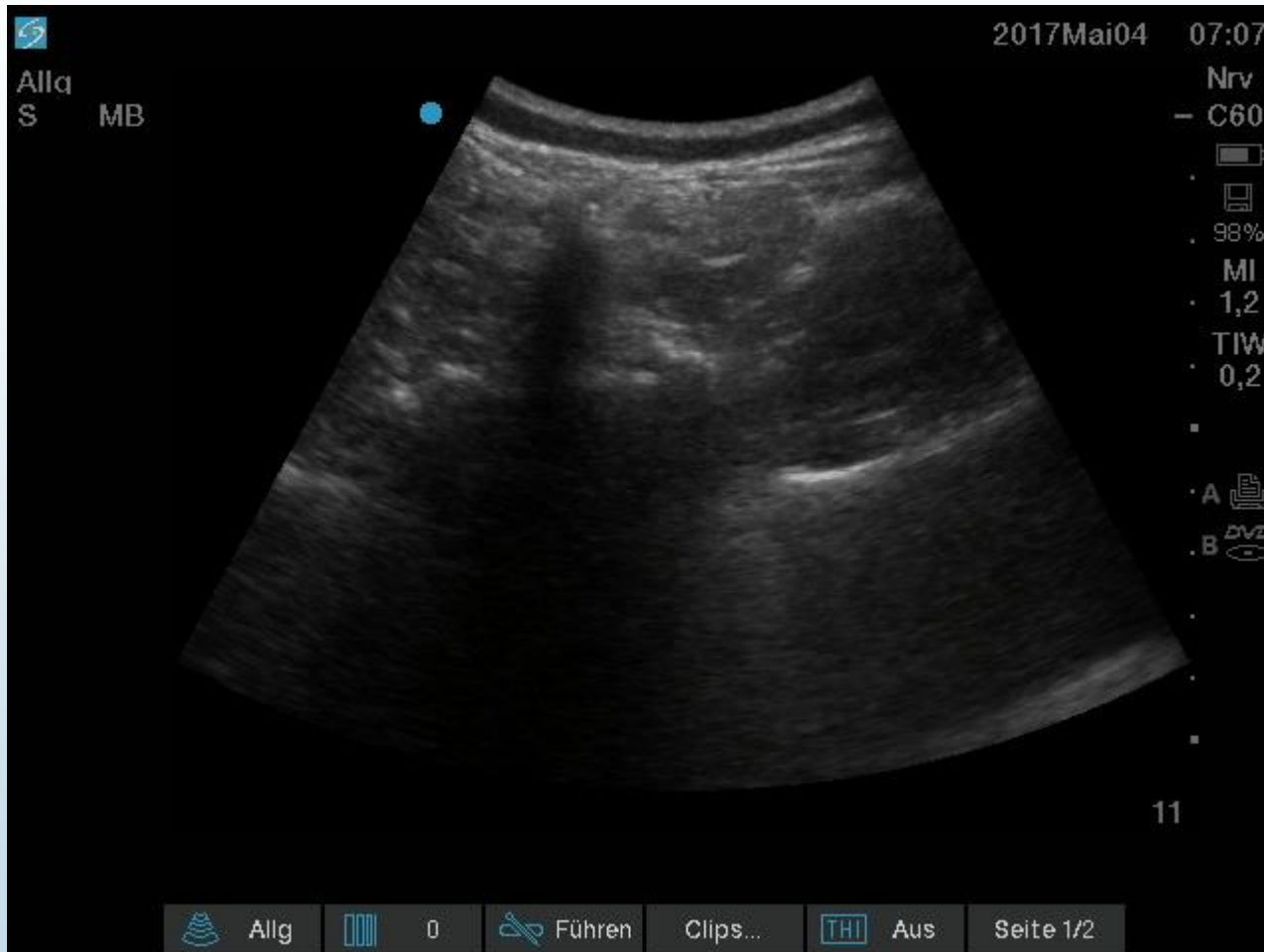***Shim JK, Moon JC, Yoon KB, Kim WO, Yoon DM. Ultrasound-Guided Lumbar Medial-Branch Block: A Clinical Study With Fluoroscopy Control. Regional Anesthesia and Pain Medicine 2006; Vol. 31 No. 5 September – October 2006***



Ultrasonographic longitudinal paravertebral view with the needle at the cephalad margin of the transverse process. TP, transverse process.

*Shim JK, Moon JC, Yoon KB, Kim WO, Yoon DM. Ultrasound-Guided Lumbar Medial-Branch Block: A Clinical Study With Fluoroscopy Control. Regional Anesthesia and Pain Medicine 2006; Vol. 31 No. 5 September – October 2006*





**Table 4.** Visual analogue scale (VAS) score after facet block (mean value)

	VAS score (mean value)	
	Before procedure	After procedure
Ultrasonography-guided group	7.5 (5-9)	2.8 (2-6)
Fluoroscopy-guided group	7.8 (4-10)	2.7 (2-5)

*p*-value < 0.05.

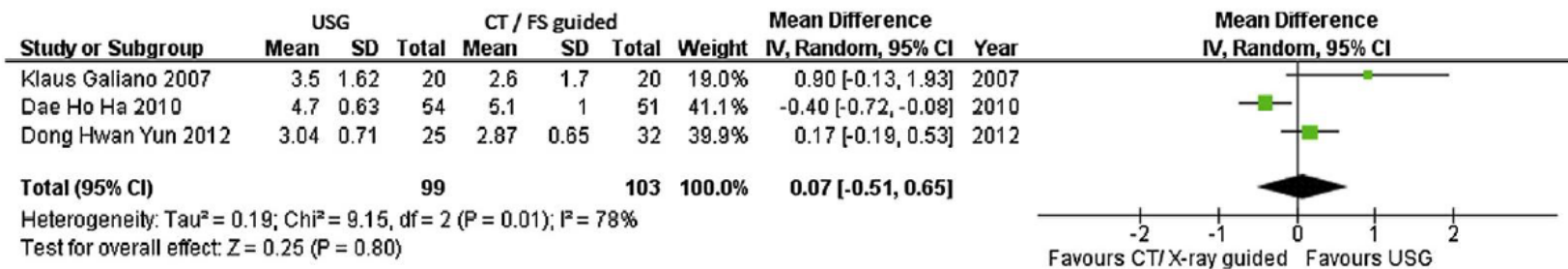
*Ha, Shim et al Comparison of Ultrasonography and Fluoroscopy guided Facet Joint block in the lumbar Spine Asian Spine Journal 2010 4/15-22*

**Table 1** Characteristics of the enrolled studies

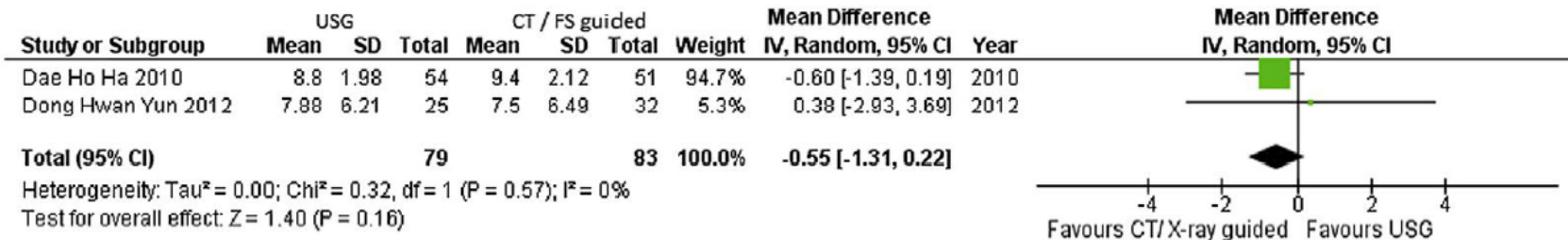
Study	Population	Age (y), Mean $\pm$ SD or Mean (Range)	Body Mass Index, Mean $\pm$ SD	Intervention	Sample Size	Study Design	Main Evaluation Index
Galiano et al <sup>14</sup>	Patients with facet joint pain and local pain increase over the facet joint with extension maneuvers.	49 $\pm$ 9.9	27 $\pm$ 4.5	USG vs CT-guided injection: 1mL of 1% lidocaine plus 1mL of 0.5% bupivacaine hydrochloride plus 1mL (4mg) of betamethasone.	40	RCT	Accuracy rate, decreased pain score after injection, mean procedure duration, and radiation doses.
Ha et al <sup>18</sup>	Patients with spinal stenosis and low back pain showed no improvement of symptoms after medication, physical therapy, and exercise therapy for >3 months.	57.2 (45–83)	NA	USG vs fluoroscopy-guided injection: dexamethasone plus 2% lidocaine were mixed at a volume of 0.5mL.	105	RCT	Decreased Modified Oswestry Disability score, decreased pain score after injection, and mean procedure duration.
Yun et al <sup>15</sup>	Patients with facet syndrome of the lumbar spine of the L4-5 and L5-S1 levels.	56.4 $\pm$ 9.2	24 $\pm$ 2.4	USG vs fluoroscopy-guided injection: 10mg of triamcinolone plus 2mL of 1% lidocaine.	57	RCT	Decreased Modified Oswestry Disability score, decreased pain score after injection, and mean procedure duration.

Abbreviation: NA, not applicable.

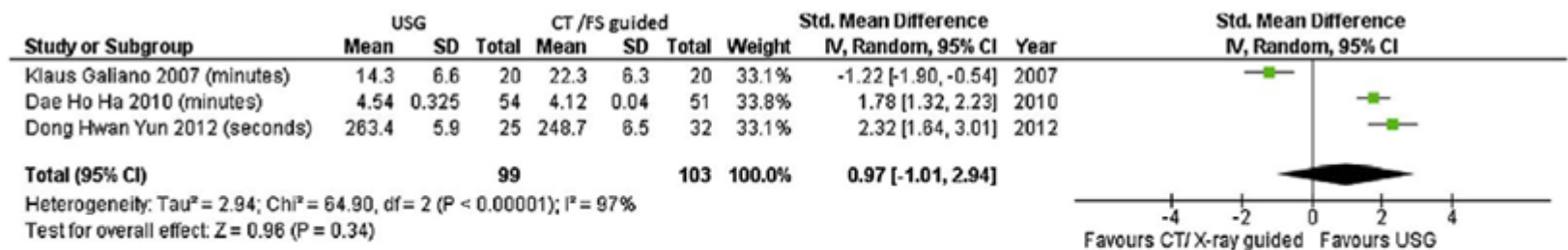
*Wu T, Zhao W, Dong Y. Effectiveness of Ultrasound-Guided Versus Fluoroscopy of Computed Tomography Scanning Guidance in Lumbar Facet Joint Injections in Adults with Facet Joint Syndrome: A Meta-Analysis of Controlled Trial. Archives of Physical Medicine and Rehabilitation 2016;97:1558-63*



**Fig 2** Change in pain score after injection: Forest plot. Abbreviation: FS, fluoroscopy.



Change in Modified Oswestry Disability score after injection: Forest plot. Abbreviation: FS, fluoroscopy.



Mean procedure duration: Forest plot. Abbreviations: FS, fluoroscopy; Std., standard.

**Design.** In 10 cadavers preserved with Thiel's method, electrodes with 10mm active tips were placed in supine position on the right using a fluoroscopic-guided technique, and on the left using a CT-guided technique. Using a special dissection approach, the relationship between the target nerve and the tip of the electrode was revealed. The displacement between electrode and the nerve, and the extent to which the electrode was parallel to the nerve, were measured with callipers.

**Results.** Under fluoroscopy guidance, electrodes were placed accurately beside the nerve, and were parallel to it for  $9 \pm 1.9$  mm. In only two cases did the electrode pass too deeply. Under CT guidance, electrodes often failed to reach the nerve, but when they did they were parallel to it for only  $3.2 \pm 3.2$  mm. In seven cases, the electrode passed too deeply beyond the target nerve.

**Conclusion.** The fluoroscopy-guided technique can be relied upon to achieve optimal placement of electrodes on the lumbar medial branches. The CT-guided technique fails to do so, and should not be used in practice until a modified version has been developed and validated



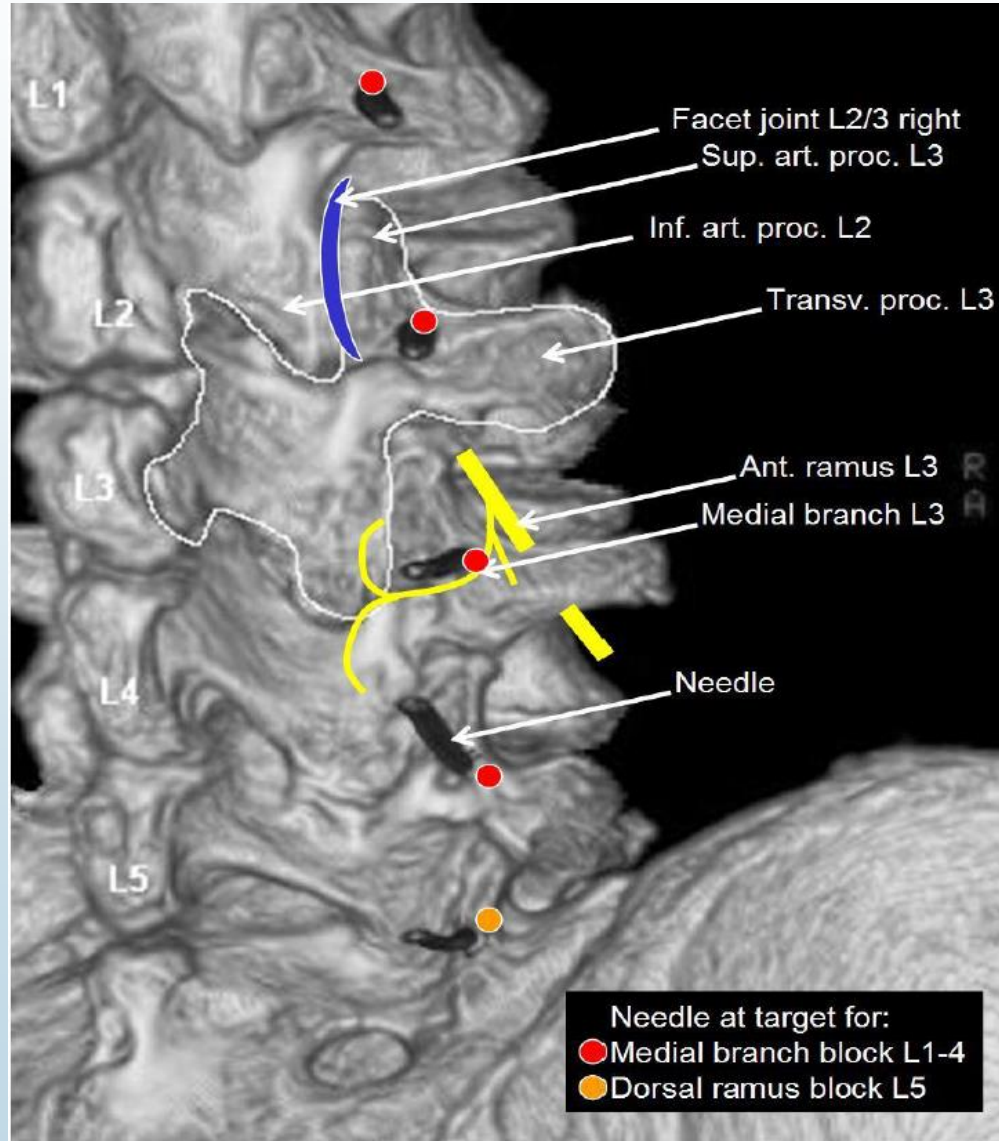
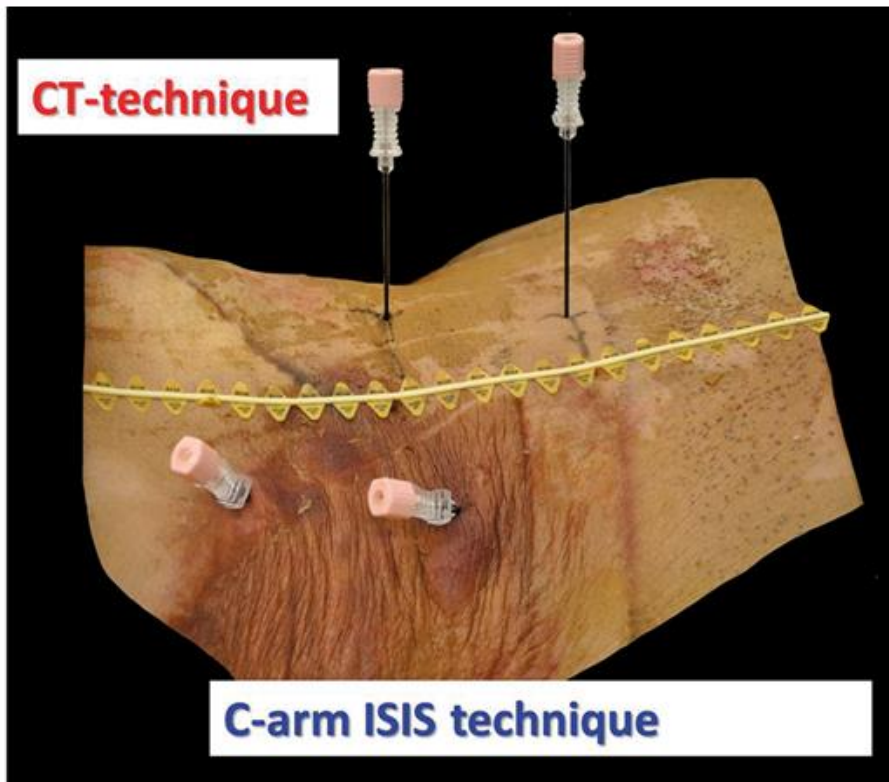


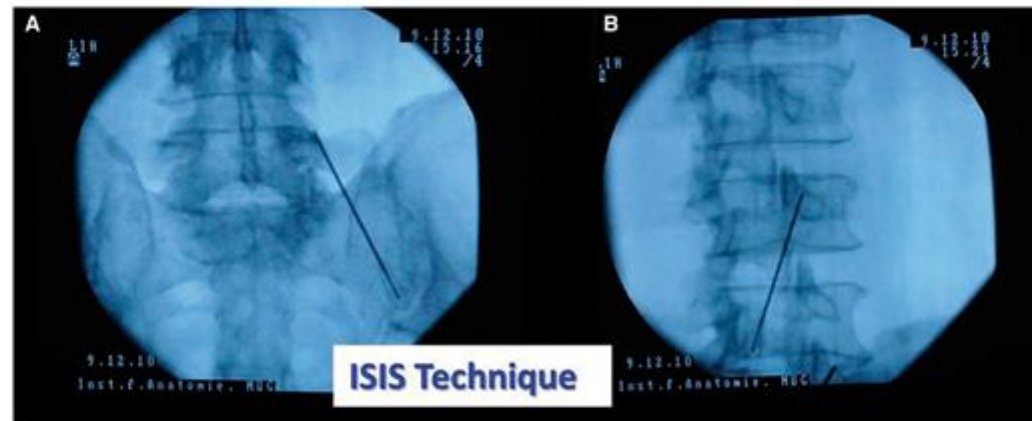
Figure 1



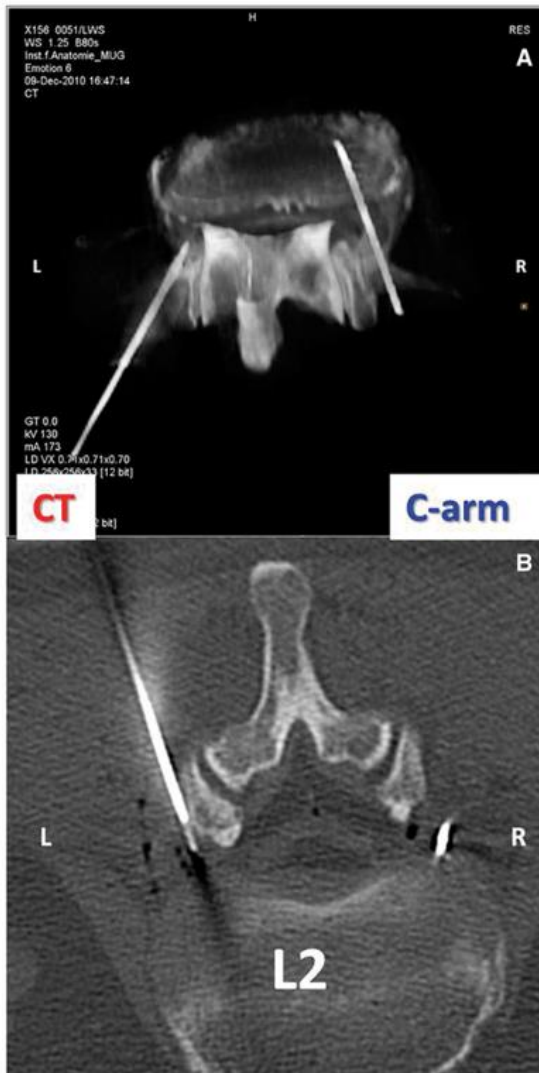
A photograph of an undissected cadaver in which electrodes have been placed on the left under CT guidance, and in the right under flouroscopy guidance. The line marks the midline and location of the tips of the spinous processes.

*Feigl et al., Thermocoagulation of the Medial Branch of the Dorsal Branch of the Lumbal Spinal Nerve: Flouroscopy Versus CT. Pain Medicine. Volume 18, Issue 1, January 2017.*

**Figure 2**



Radiographs of fluoroscopy views of electrodes. (A) Antero-posterior view of an electrode at L4. (B) Oblique lateral view of an electrode at L3.



CT images of electrodes placed in a cadaver, inserted under CT on the left, and fluoroscopy in the right. (A) Reconstructed view. (B) Axial view. Note that the needle inserted under fluoroscopy has been advanced to a deeper location before transport, and has not been withdrawn to its original position.

***Feigl et al., Thermocoagulation of the Medial Branch of the Dorsal Branch of the Lumbar Spinal Nerve: Fluoroscopy Versus CT. Pain Medicine. Volume 18, Issue 1, January 2017.***

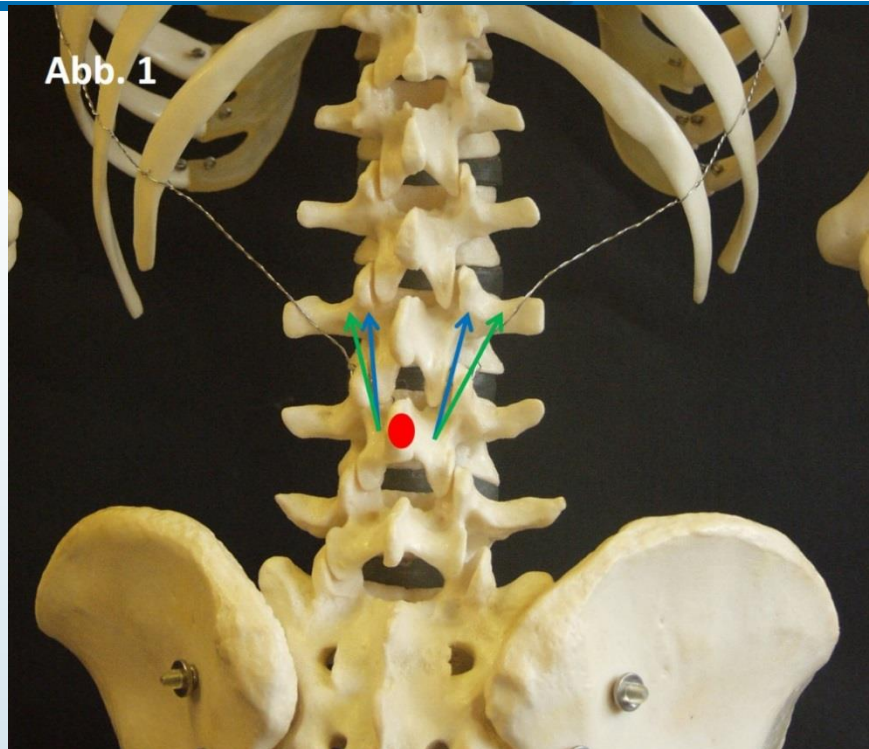


Abbildung 1: Die Abbildung zeigt die Nadelpositionierungstechnik. Ausgehend vom Processus spinosus (roter Punkt) wird die Nadel nach lateral und kranial vorgeschoben. Zielpunkt ist dabei der Unterrand des Processus articularis superior des nächst kranial gelegenen Wirbels (blauer Pfeil). Dann wird die Nadel lateral am Processus articularis superior vorbeigeschoben (grüner Pfeil).

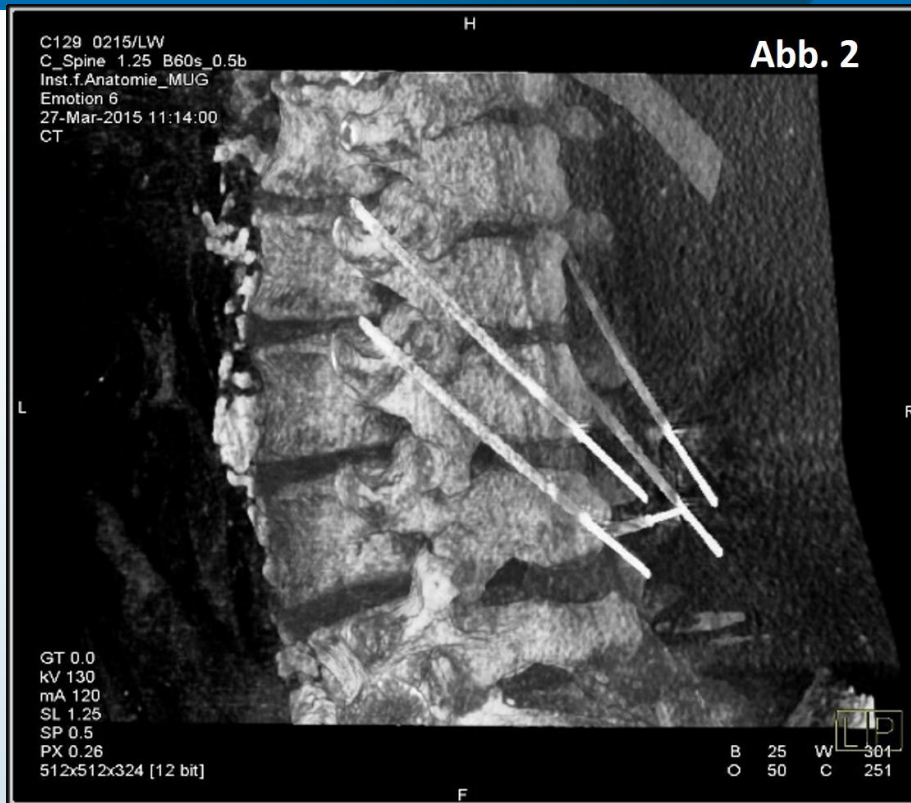

Abbildung 2: Die Abbildung zeigt eine 3D-Rekonstruktion nach erfolgter Nadelpositionierung. Man beachte bitte, dass die Nadeln zur Vermeidung der Dislokation bis Knochenkontakt vorgeführt wurden.

Abb. 4

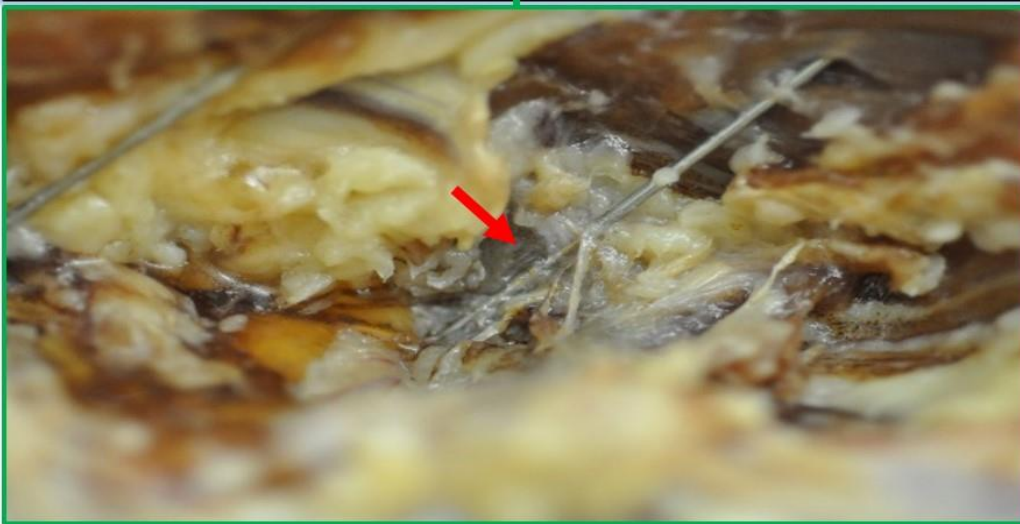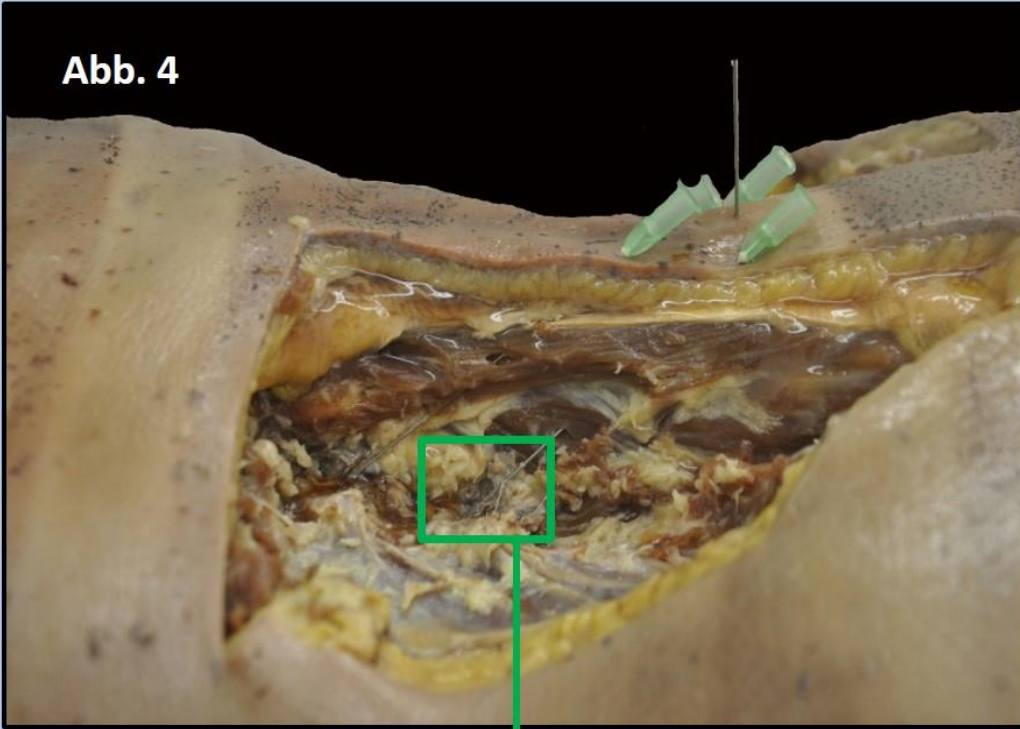
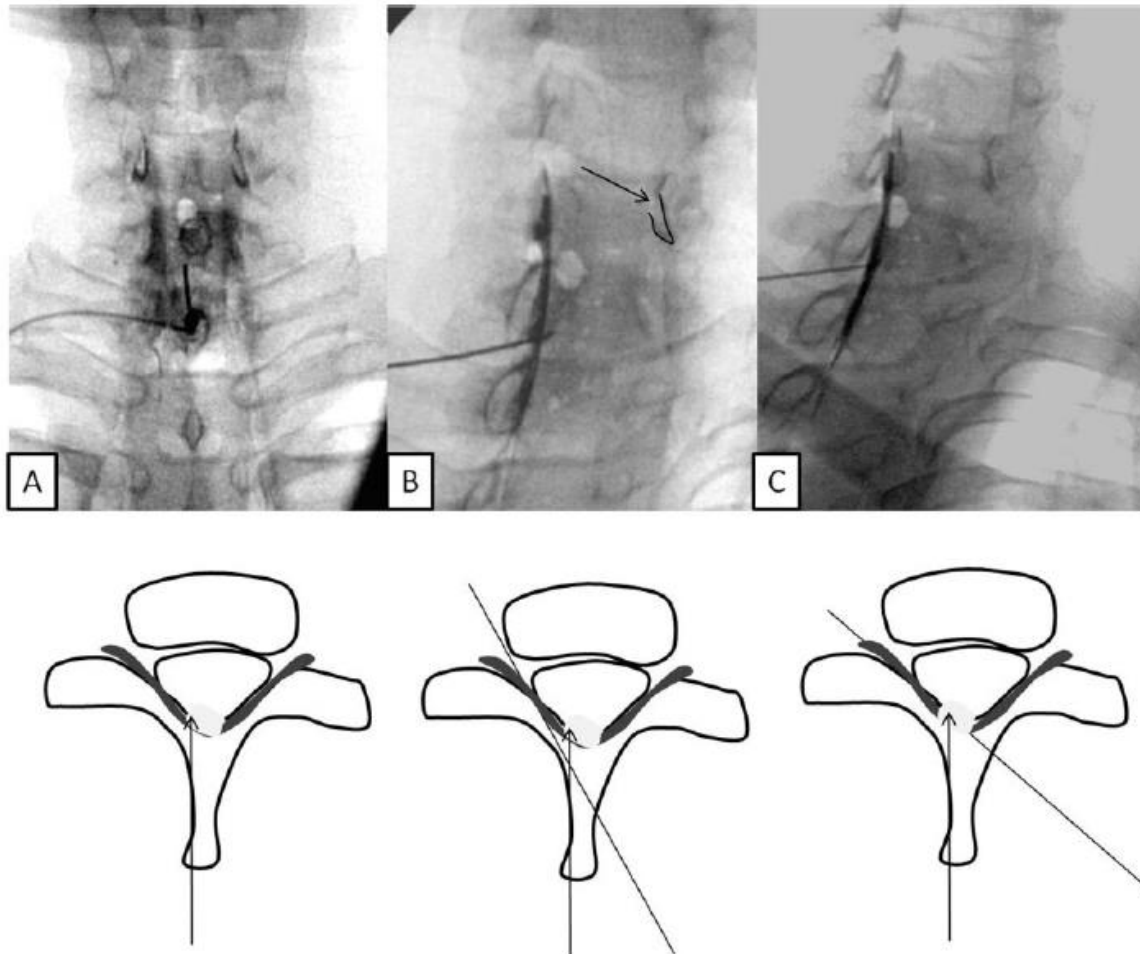


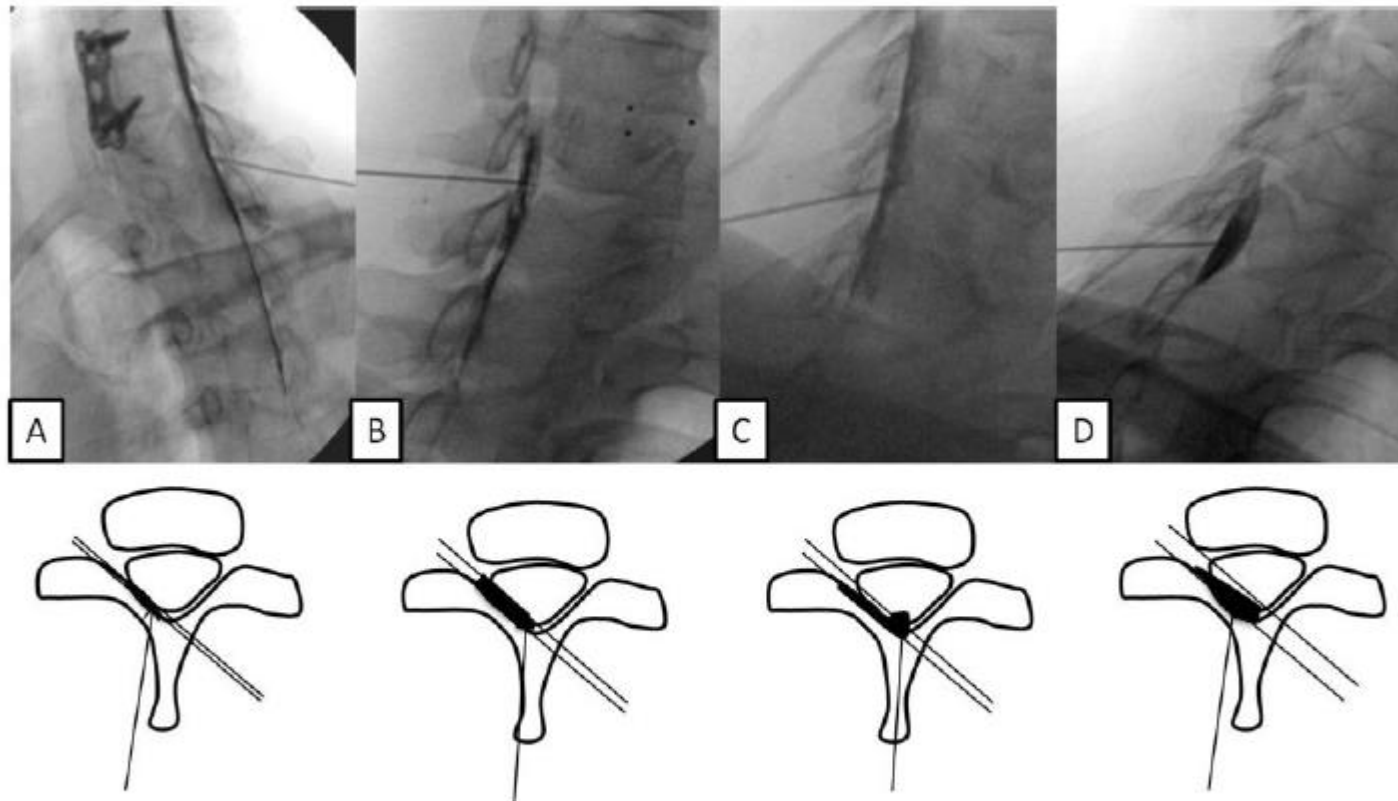
Abbildung 4: Die Abbildung zeigt eine linke Seite mit erfolgreicher Nadelpositionierung.

*Feigl et al., Anatomische Untersuchung einer neuen Stichtechnik für lumbale CT-gezielte Thermokoagulationen des Ramus medialis rami dorsalis nervi spinalis*

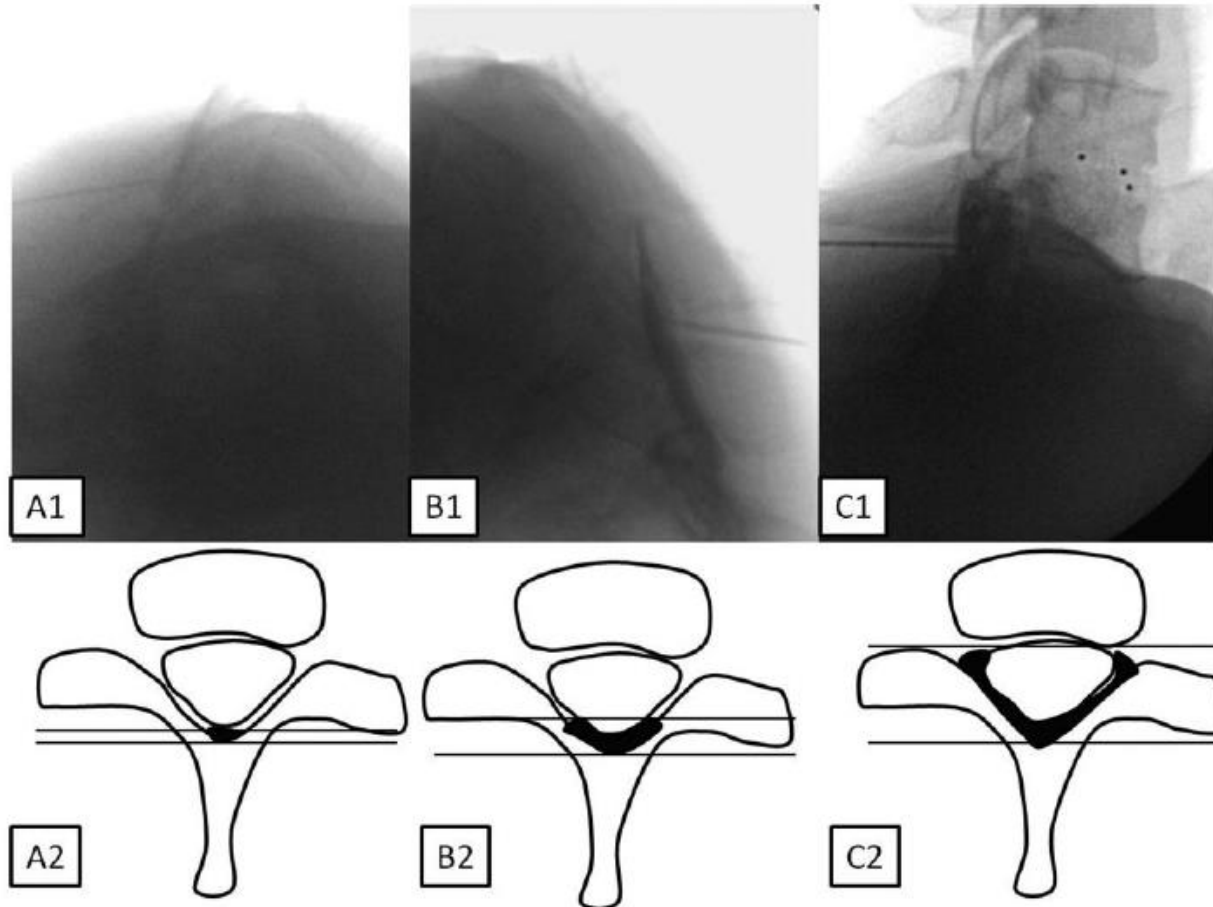


**Figure 6** Fluoroscopic and diagrammatic depiction of the changing relationship of the needle tip in relation to the contrast spread with increasing obliquity: upper row **(A)** AP view, **(B)** CLO30 view, and **(C)** CLOm view. Lower row is the corresponding diagrammatic representation. Diagonal lines represent the fluoroscopic beam, and the arrow represents the needle. Note that the line of contrast remains in close relationship with the VILL but both the needle and the filling defect are slightly more anterior at CLO30. **(B)** The arrow points to the contralateral foraminal spread (highlighted). Note the prominent filling defect that is seen both in AP and lateral views. AP = antero-posterior; CLO30 = contralateral oblique view at obliquity of 30°; CLOm = contralateral oblique view at measured obliquity; VILL = ventral interlaminae line.

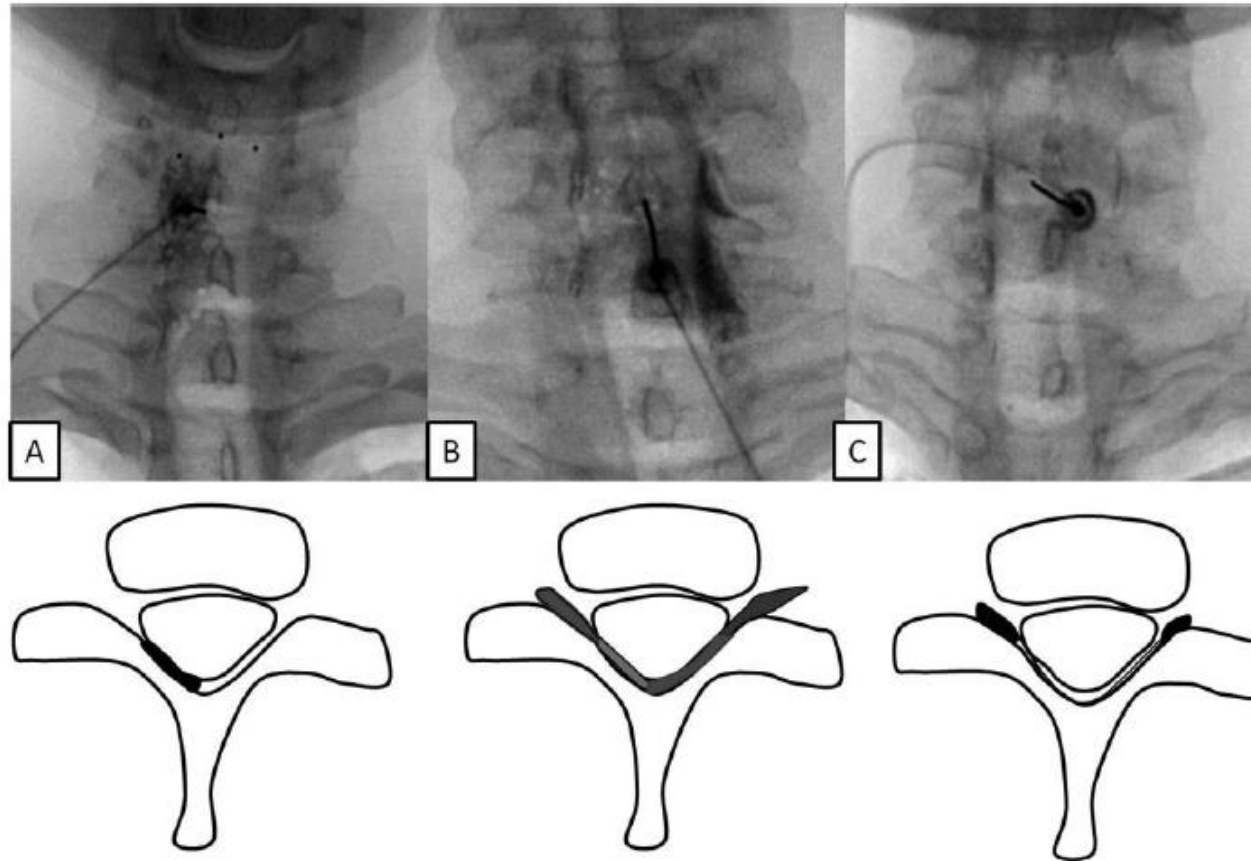




**Figure 7** Fluoroscopic and diagrammatic depiction of the relationship of the contrast margin to the needle tip: upper row left to right, needle tip location in CLOm view: **(A)** posterior to the contrast, **(B)** at the anterior margin of the contrast, **(C)** anterior to the contrast, and **(D)** obscured by the contrast. Lower row is diagrammatic representation of the same. Diagonal lines represent the fluoroscopic beam, and the arrow represents the needle.



**Figure 8** Fluoroscopic and diagrammatic depiction of various contrast patterns seen in the lateral view: three types of lateral spread and likely diagrammatic (unilateral or bilateral) correlates: **(A)** is thin line (lateral zone 1), **(B)** is a thicker line (lateral zones 1 and 2), and **(C)** is the thickest line (lateral zones 1, 2, and 3).



**Figure 9** Fluoroscopic and diagrammatic depiction of various patterns seen in the antero-posterior view: the three patterns of spread in AP view and diagrammatic correlate in lower row: **(A)** represents unilateral nonhomogenous spread with filling defect but without nerve root spread, **(B)** represents bilateral nonhomogenous spread with filling defect and with nerve root spread, **(C)** represents nerve root spread only. The filling defect likely represents repulsion of lipid and contrast.

## Conclusion

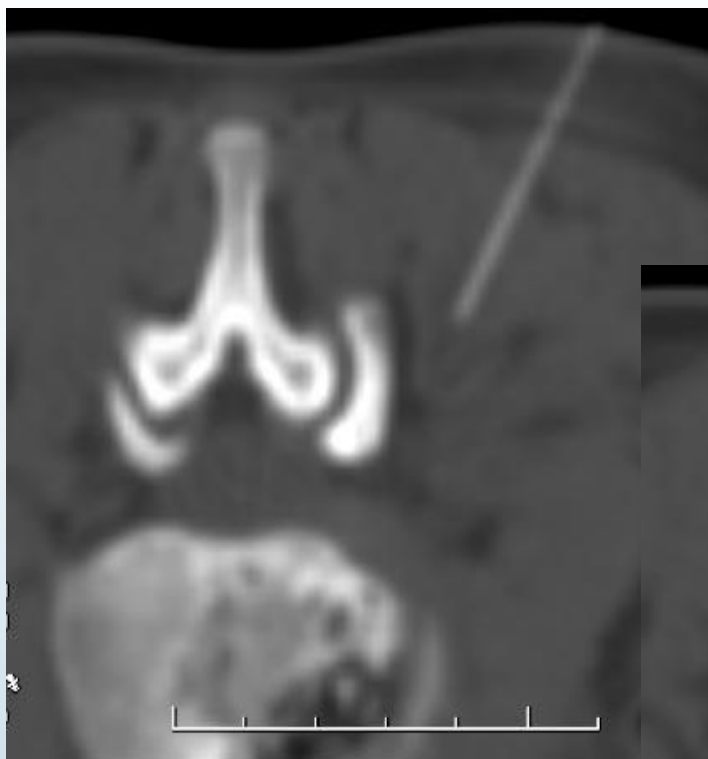
**Spread of contrast in the cervical epidural space shows multiple patterns, and the extent of dispersion is variable and unpredictable.** The CLOm view provides clear confirmation of epidural spread. The posterior margin of the contrast will invariably overlie the VILL. The contrast can appear as a thin line or as a much thicker band of spread. The needle tip usually lies within the margins of the contrast. At times, the tip may project slightly beyond the contrast margin; this may be seen particularly in midline needles and may represent an element of dural indentation. At lesser angles of obliquity, the needle appears significantly anterior to the contrast margin.

The lateral view does not provide a fixed landmark for the posterior margin of the contrast. When the posterior margin of the contrast does not overlie the spinolaminar line, then the spread should be confirmed as epidural spread by the CLO view. It is to be noted that thick spread over the articular pillars is frequently seen in the lateral view and is consistent with epidural spread. Ventral contrast spread is not visualized in the lateral view when using low volumes of contrast.

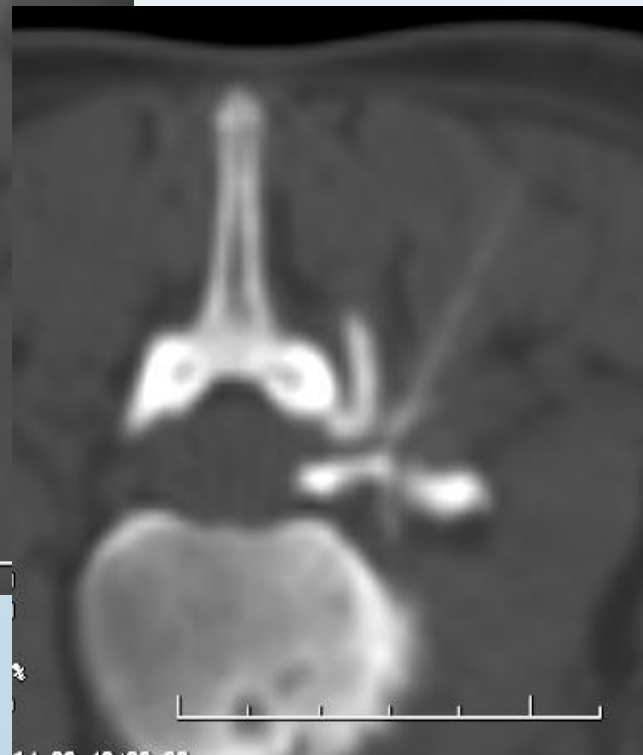
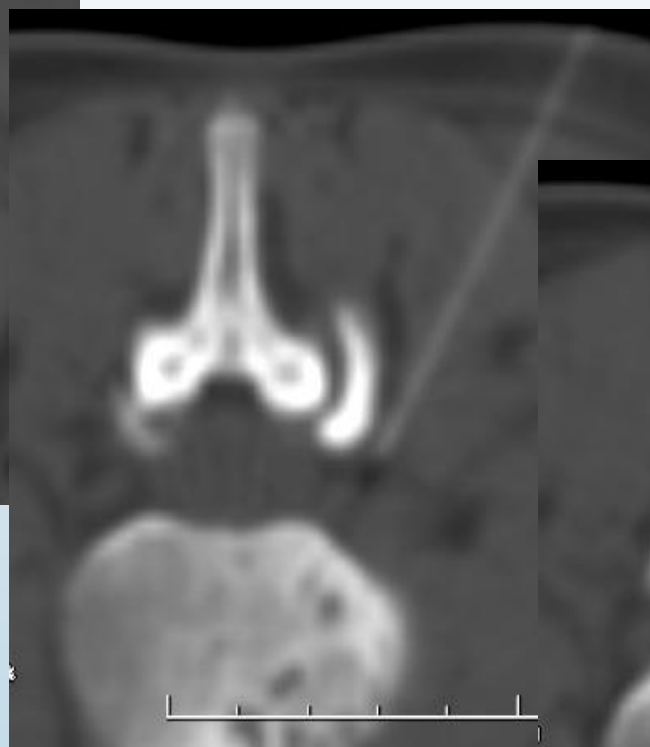
Given the consistency of the posterior margin of the epidural contrast to a radiological landmark in the CLO view, this view should be considered the optimal view to confirm epidural location of the injectate.

**The AP view is an excellent view to measure the craniocaudad spread, as well as foraminal spread. At low volumes of contrast, the AP view might provide the best estimate of the likelihood of the injectate accessing the pain-generating pathology and should be considered the optimal view for this purpose.**

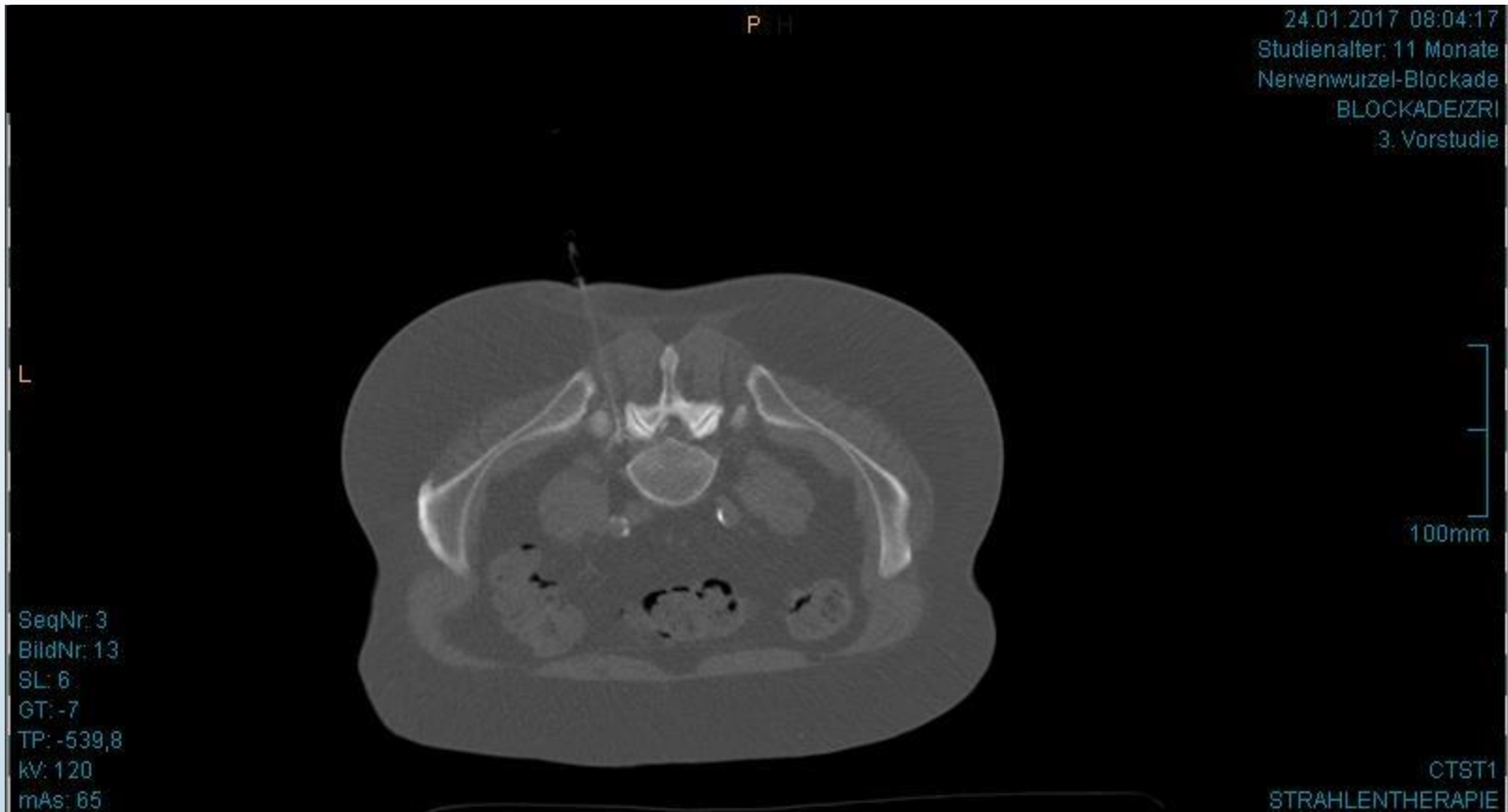Fat vacuolation is also a reassuring sign of epidural spread, but the study does not provide values of sensitivity or specificity for this phenomenon.

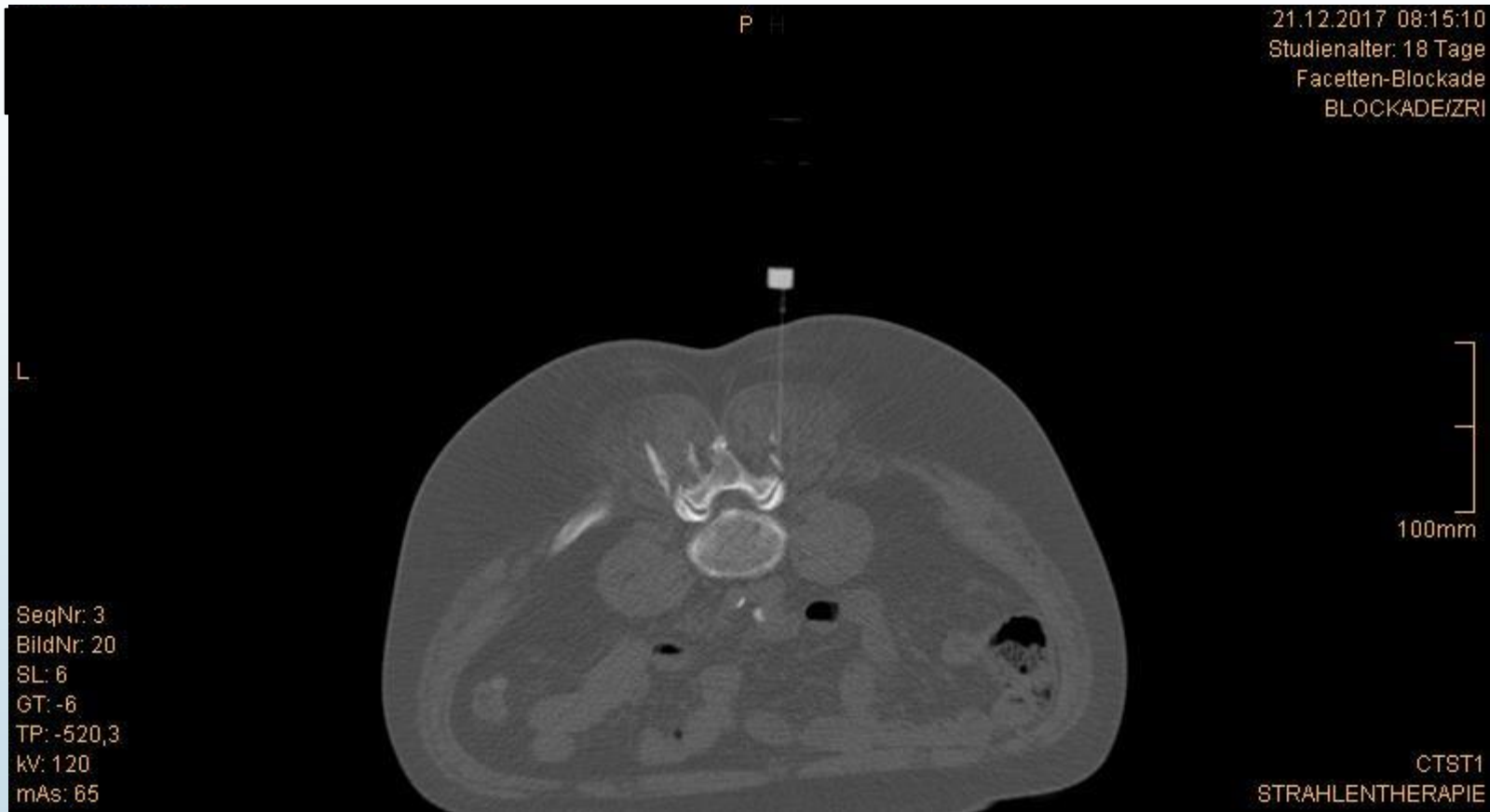

## CT-gezielte Blockadebehandlung

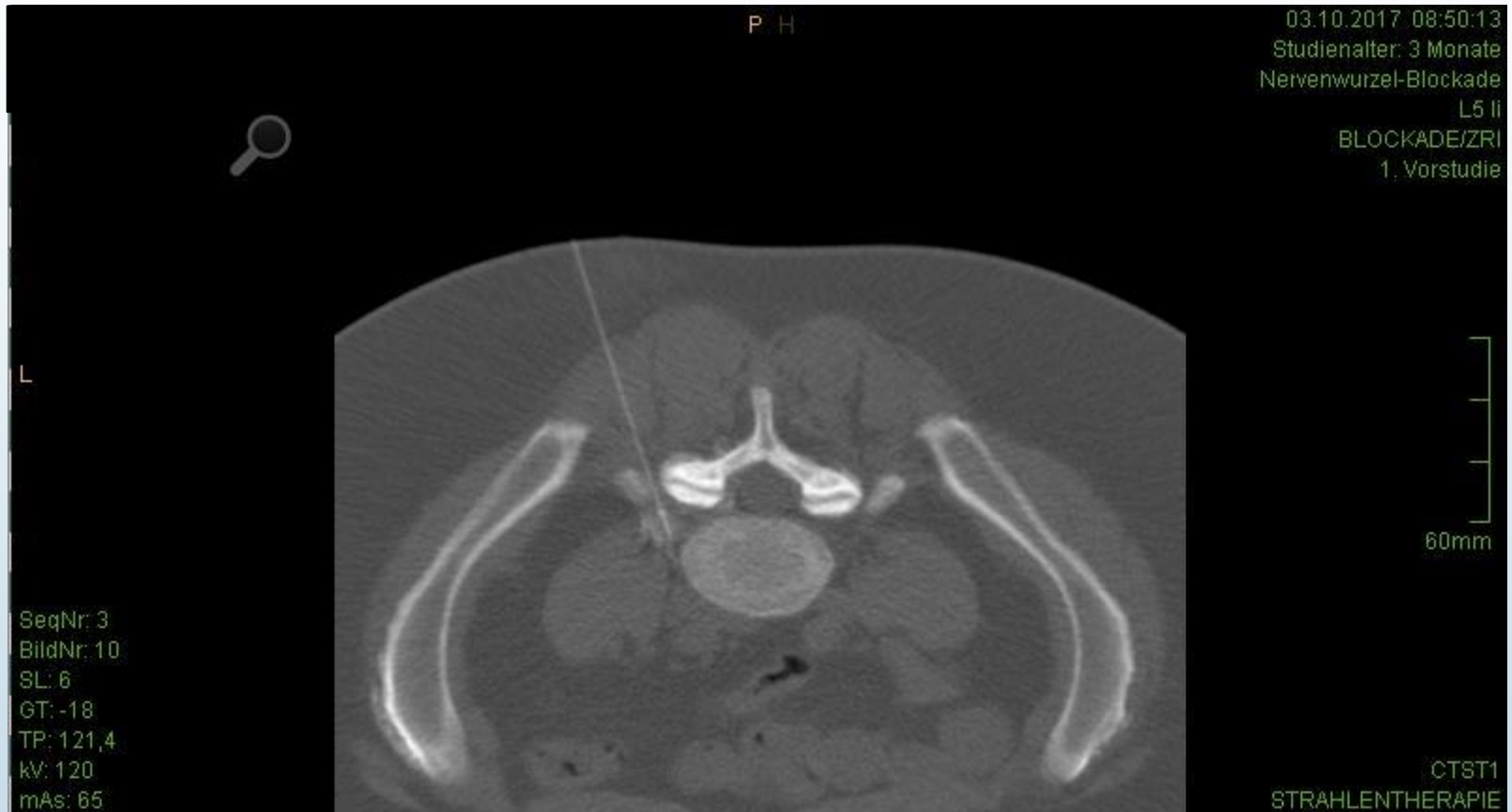


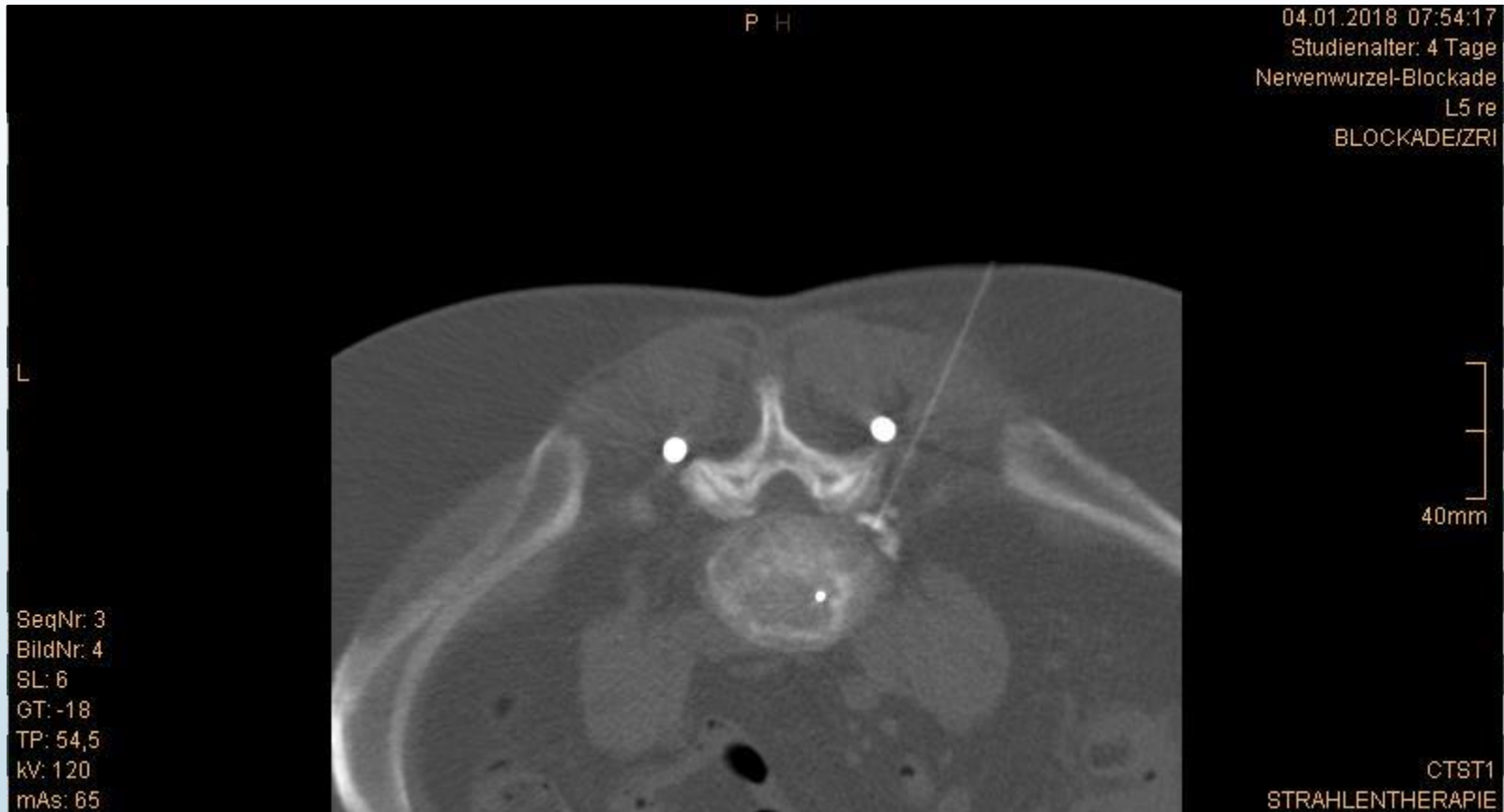## CT-gezielte peridurale NW-Blockade

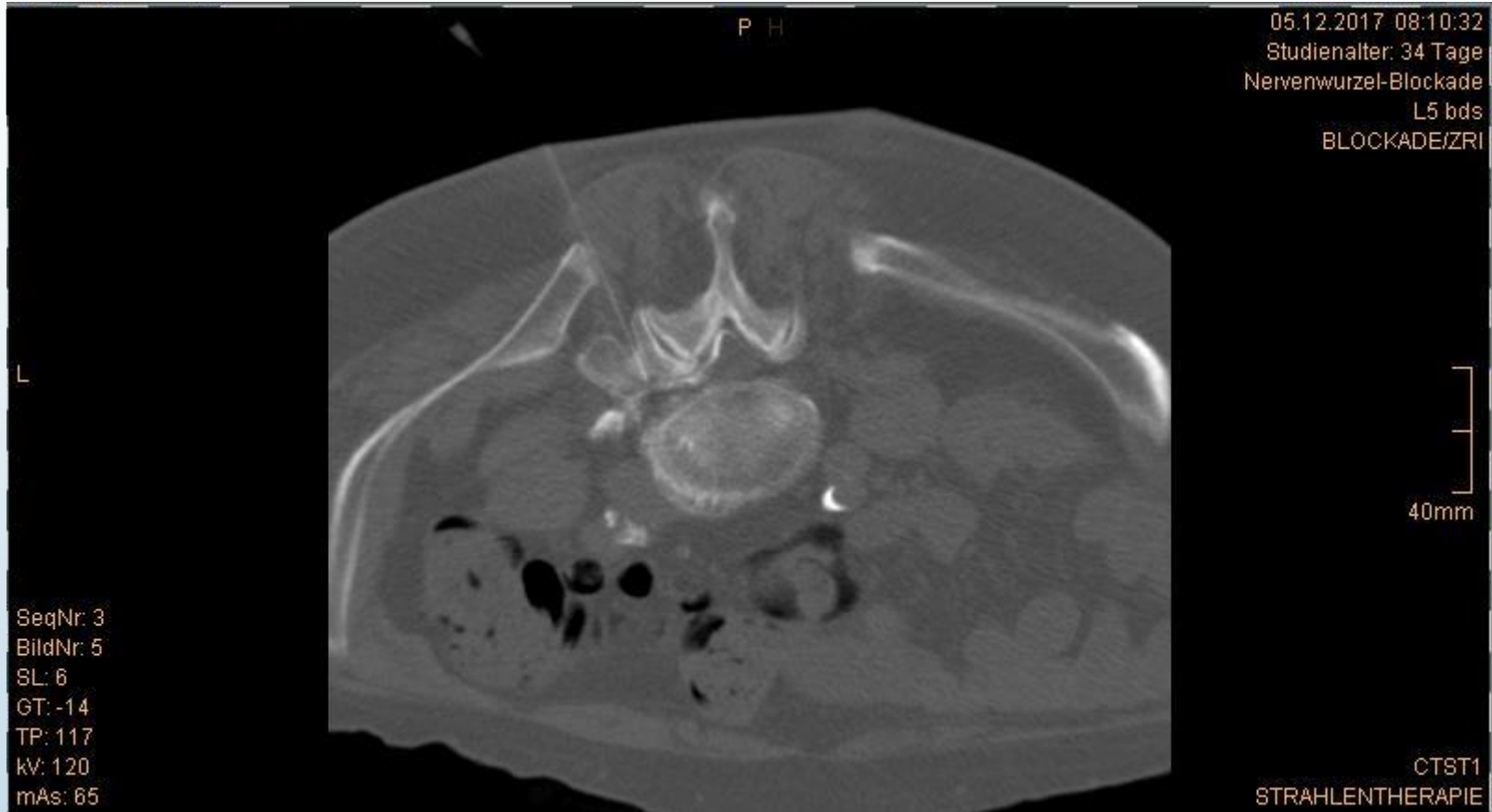

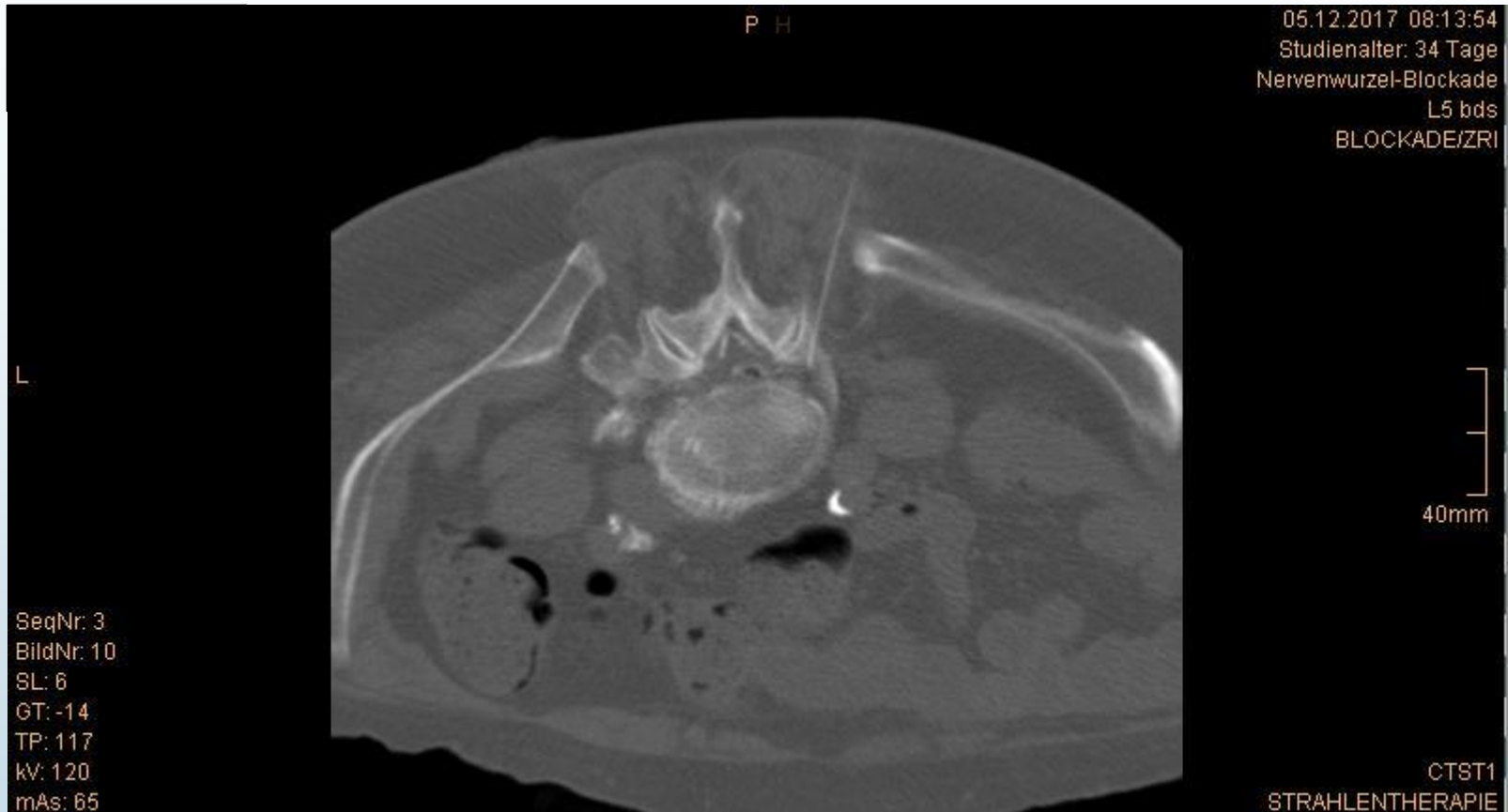



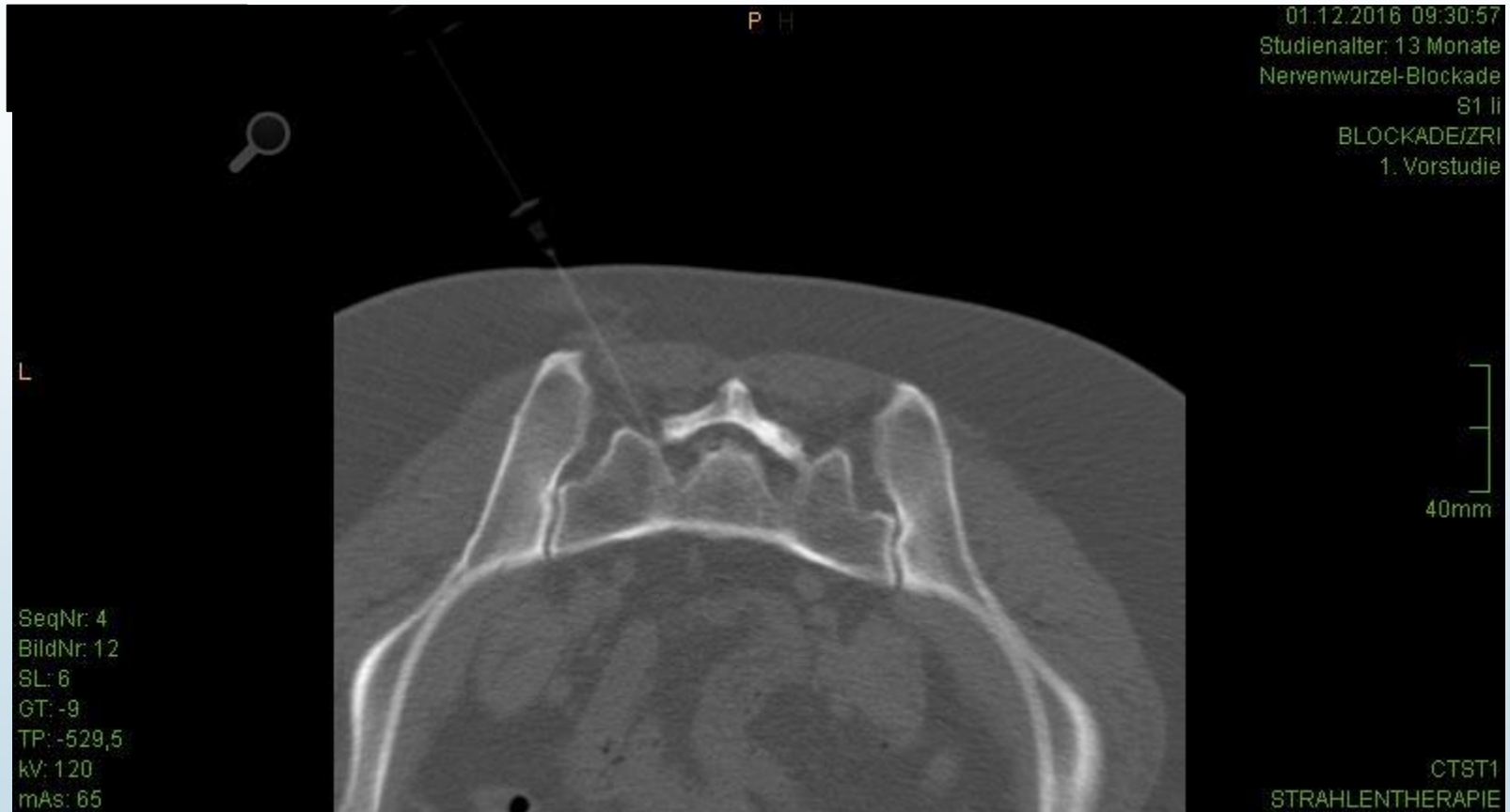


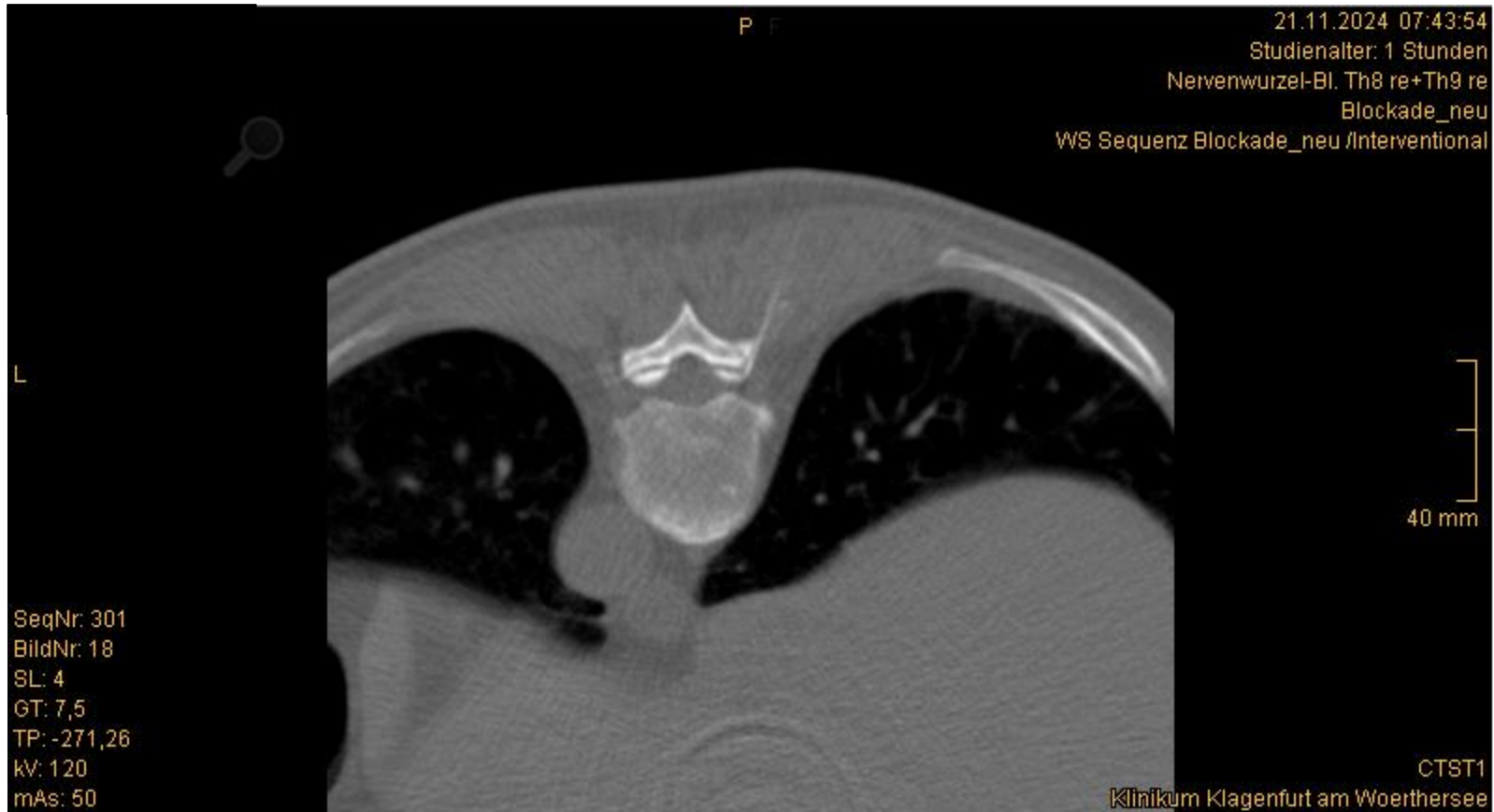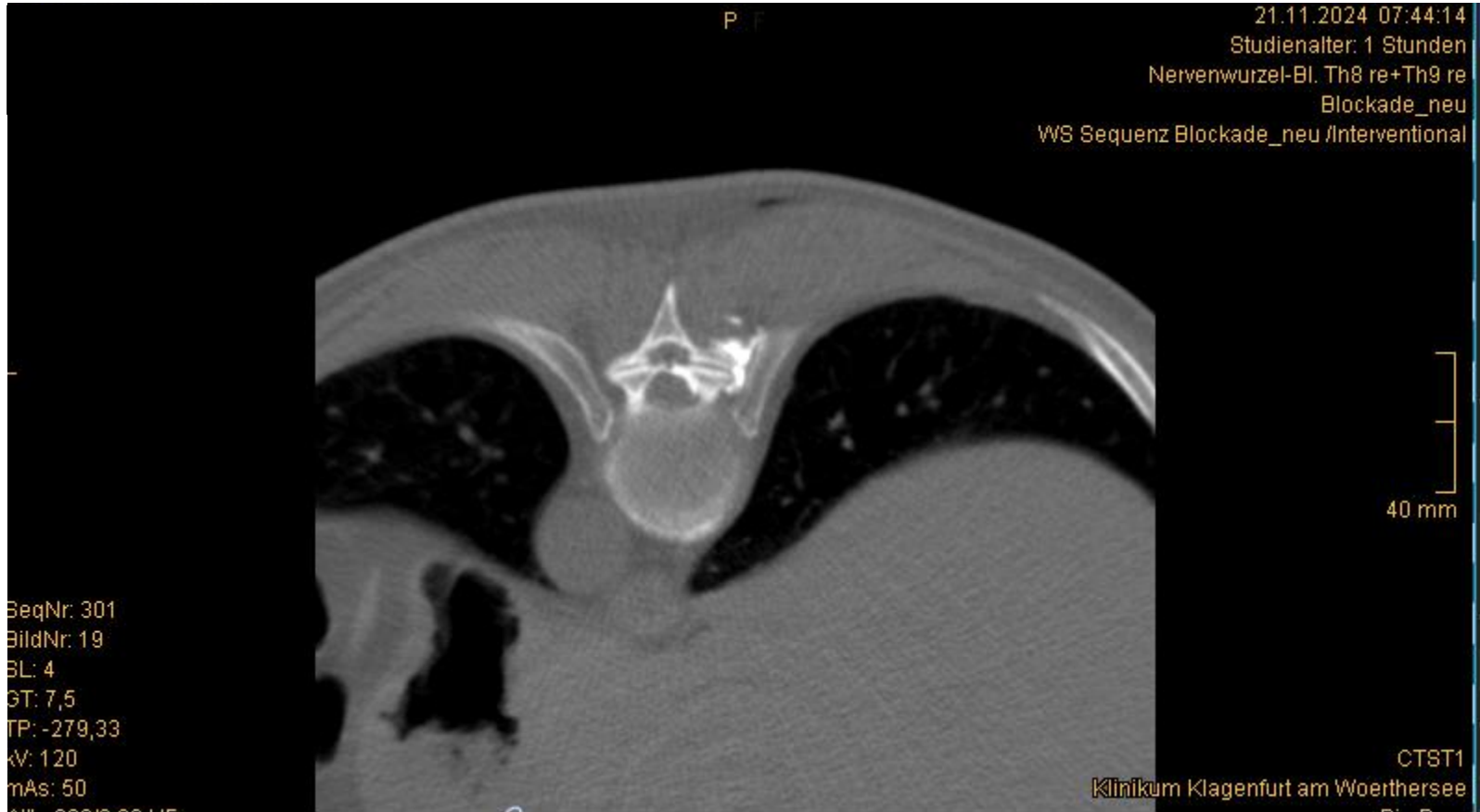












## Methods.

Forty-seven consecutive patients with degenerative LSS were enrolled in this prospective study. All subjects underwent lumbar spine magnetic resonance imaging. Two radiologists independently graded lumbar central canal stenosis based on T2-weighted axial images. All CTG-LESI were performed in the procedure room. Outcome measures were obtained using the 5-point patient's satisfaction scale at 2 and 8 weeks post-treatment. To evaluate the outcome, we divided the patients into two groups according to their response to the treatment.

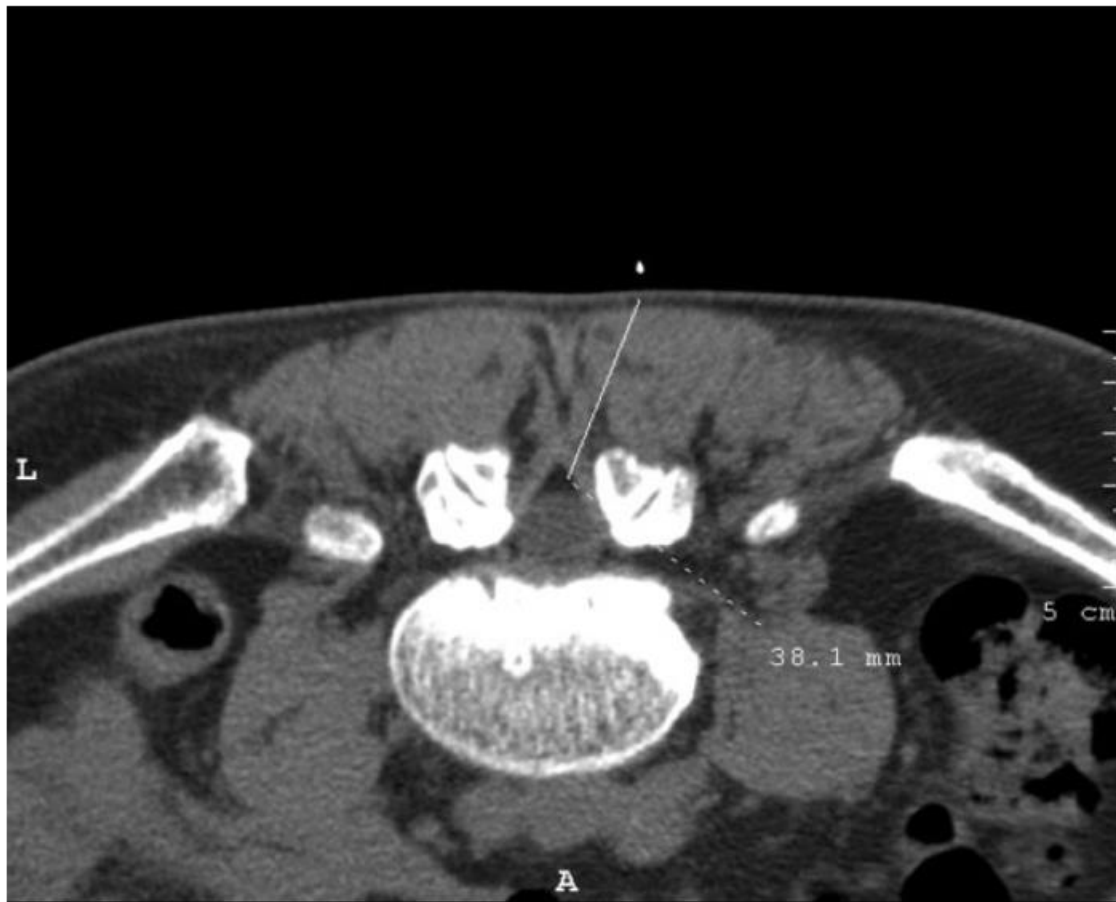## Results.

Improvement (including reports of slightly improved, much improved, and no pain) was observed in 37 patients (78.7%) at 2 weeks and 36 patients (77.6%) at 8 weeks after the procedure. There was no statistically significant correlation between pain relief and age.

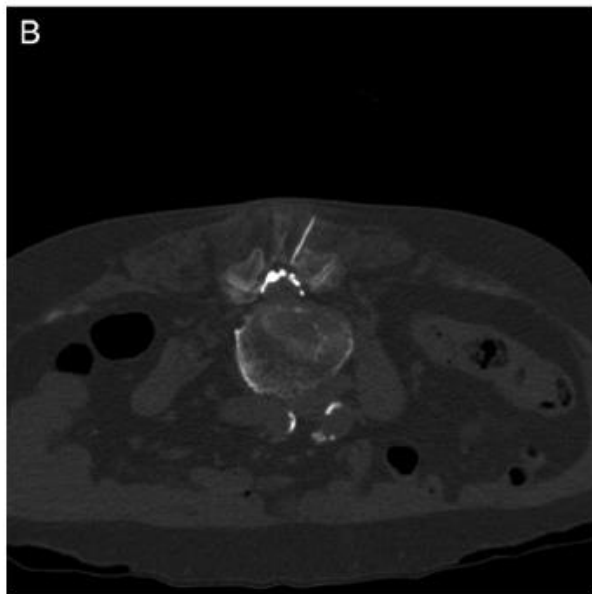
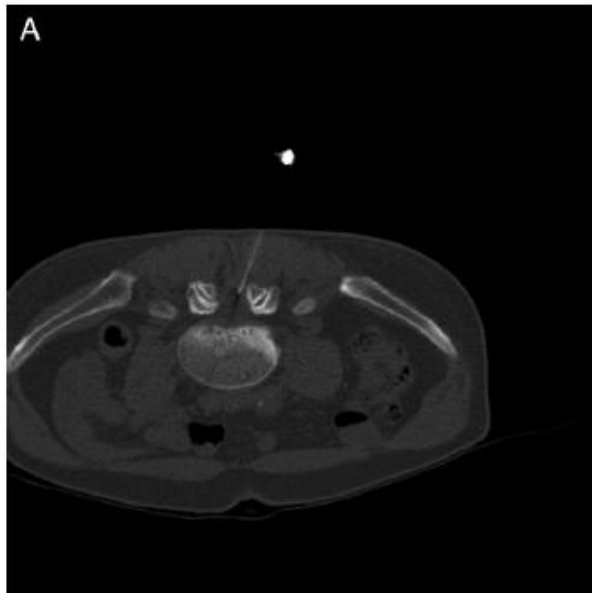
## Conclusions.

**The grade of LSS appears to have no effect on the degree of pain relief associated with CTG-LESI. However, CTG-LESI seems to provide effective short-term pain relief due to LSS.**





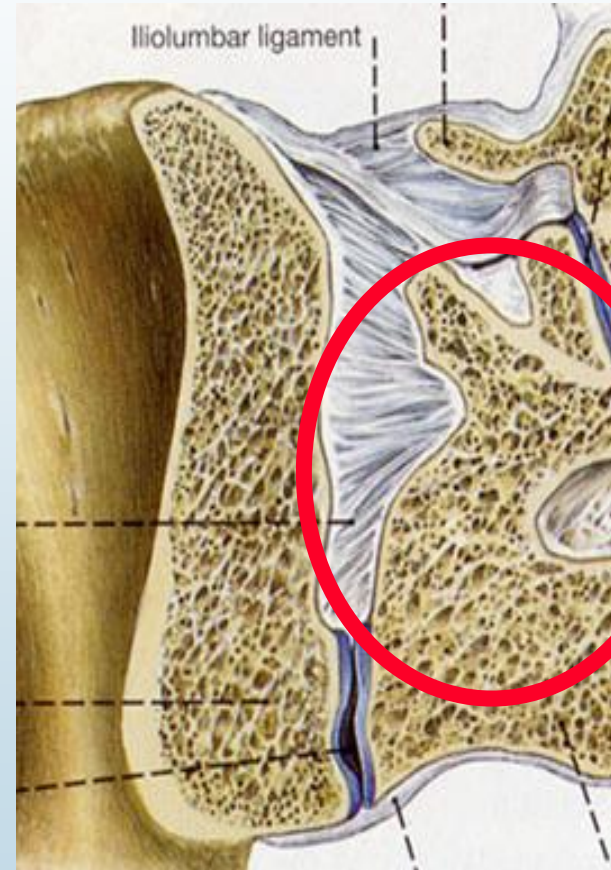
**Figure 1** Initial scout image shows the lumbar epidural space at L4–5. The distance tool was used to calculate the appropriate skin entry site.

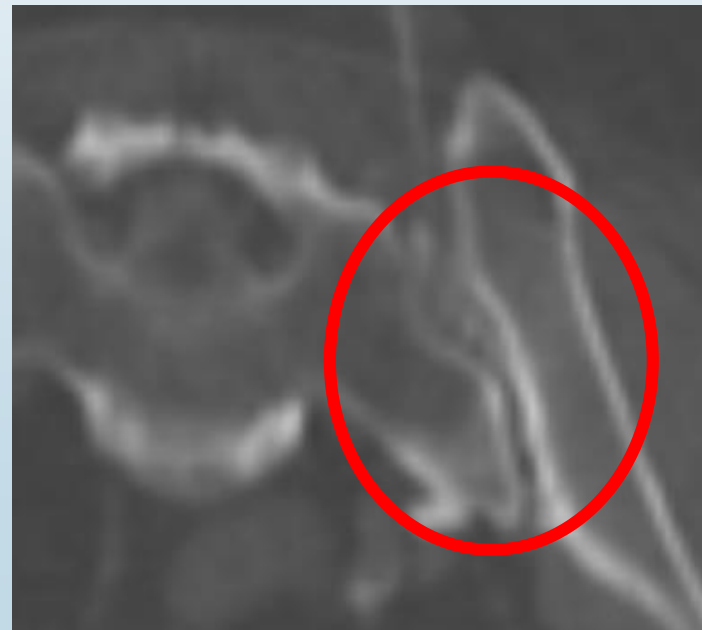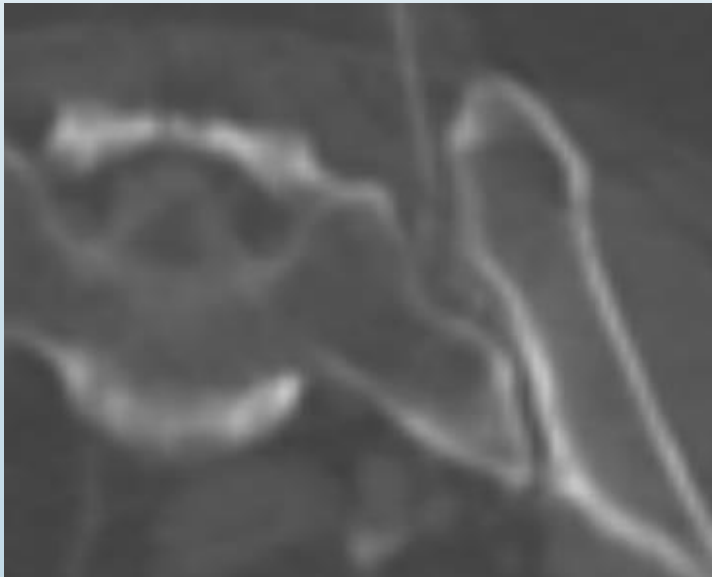
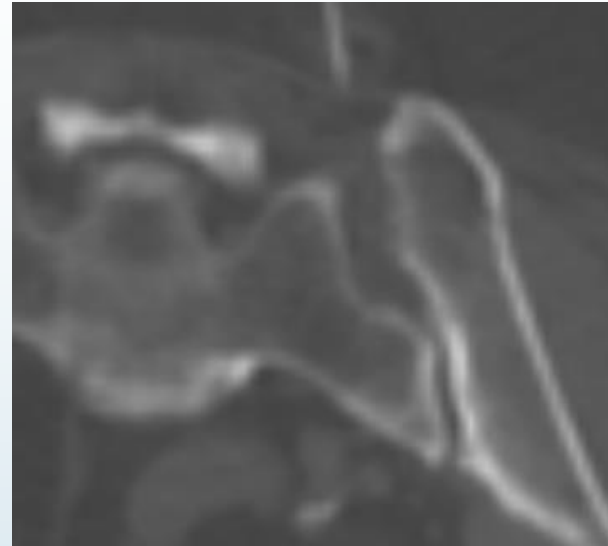
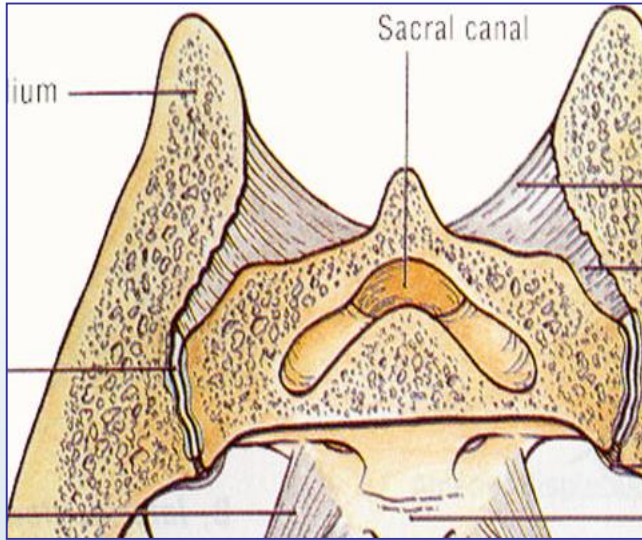


**Figure 2** A CT image reveals that the epidural needle was placed in the L4–5 epidural space (A), and shows the contrast material had spread to the lumbar epidural space (B).

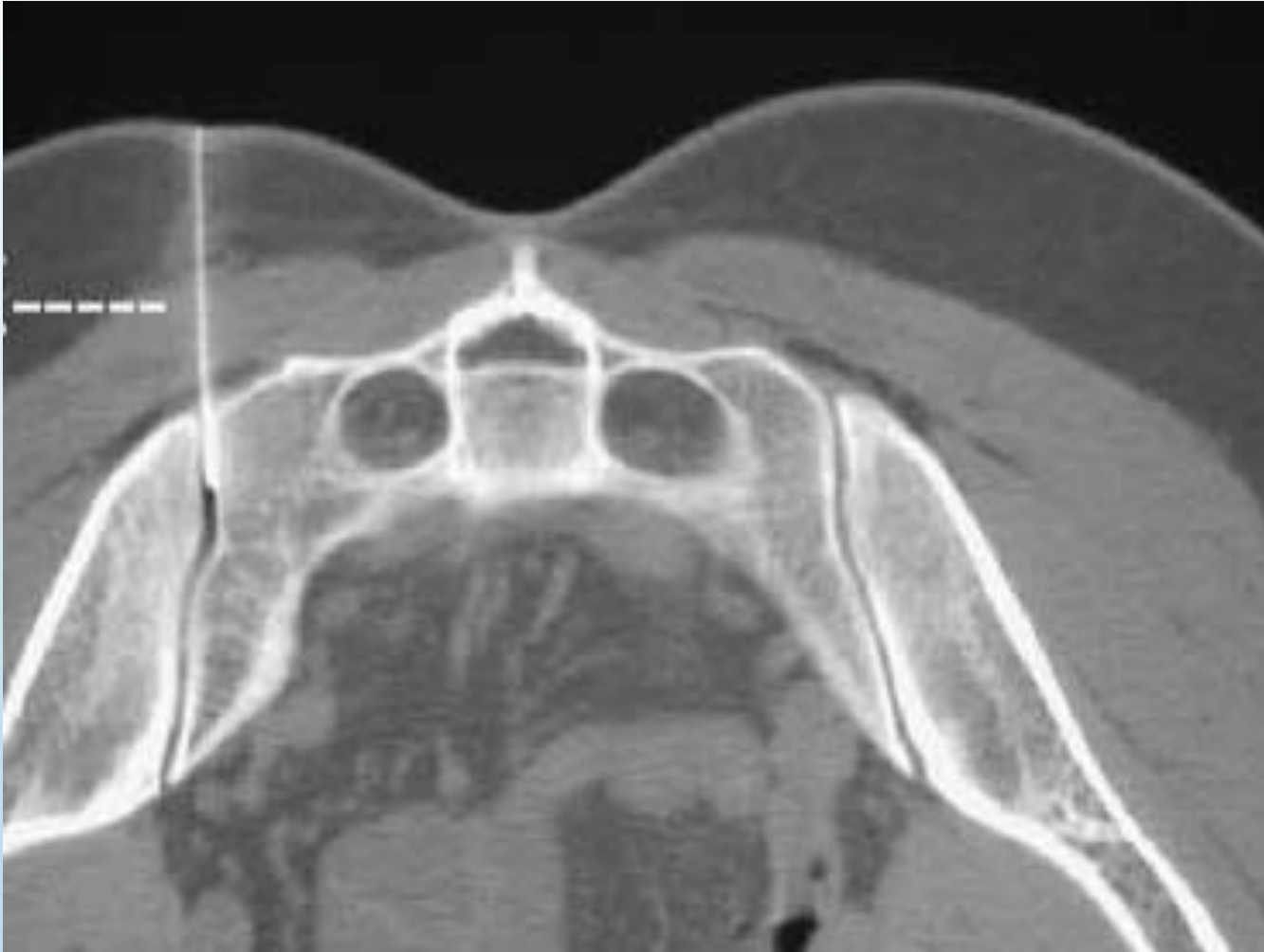*Chan-Hong P. et al.; Correlation Between Severity of Lumbar Spinal Stenosis and Lumbar Epidural Steroid Injection. Pain Medicine; 2014.*

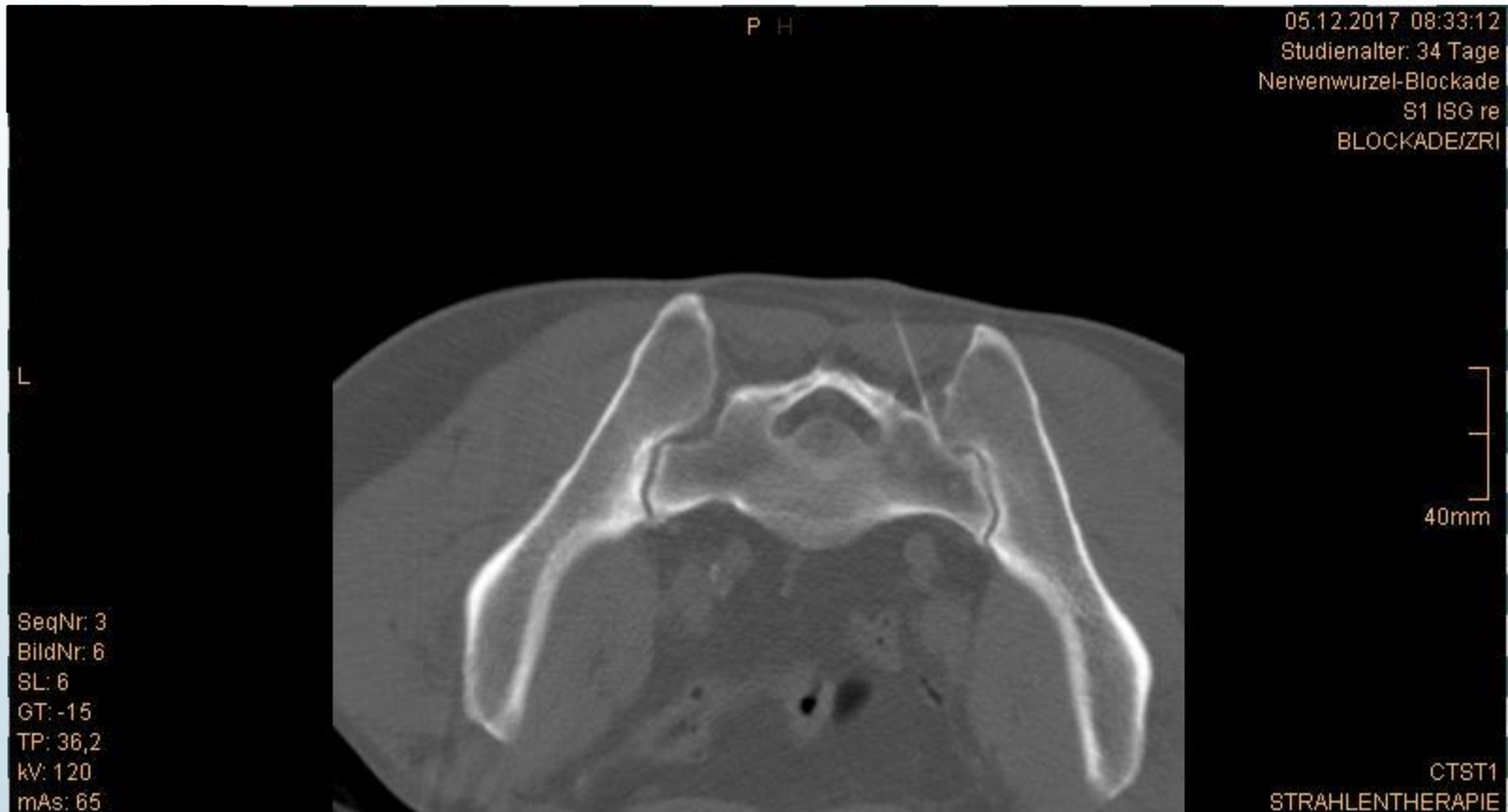# Iliosakralgelenke (ISG)

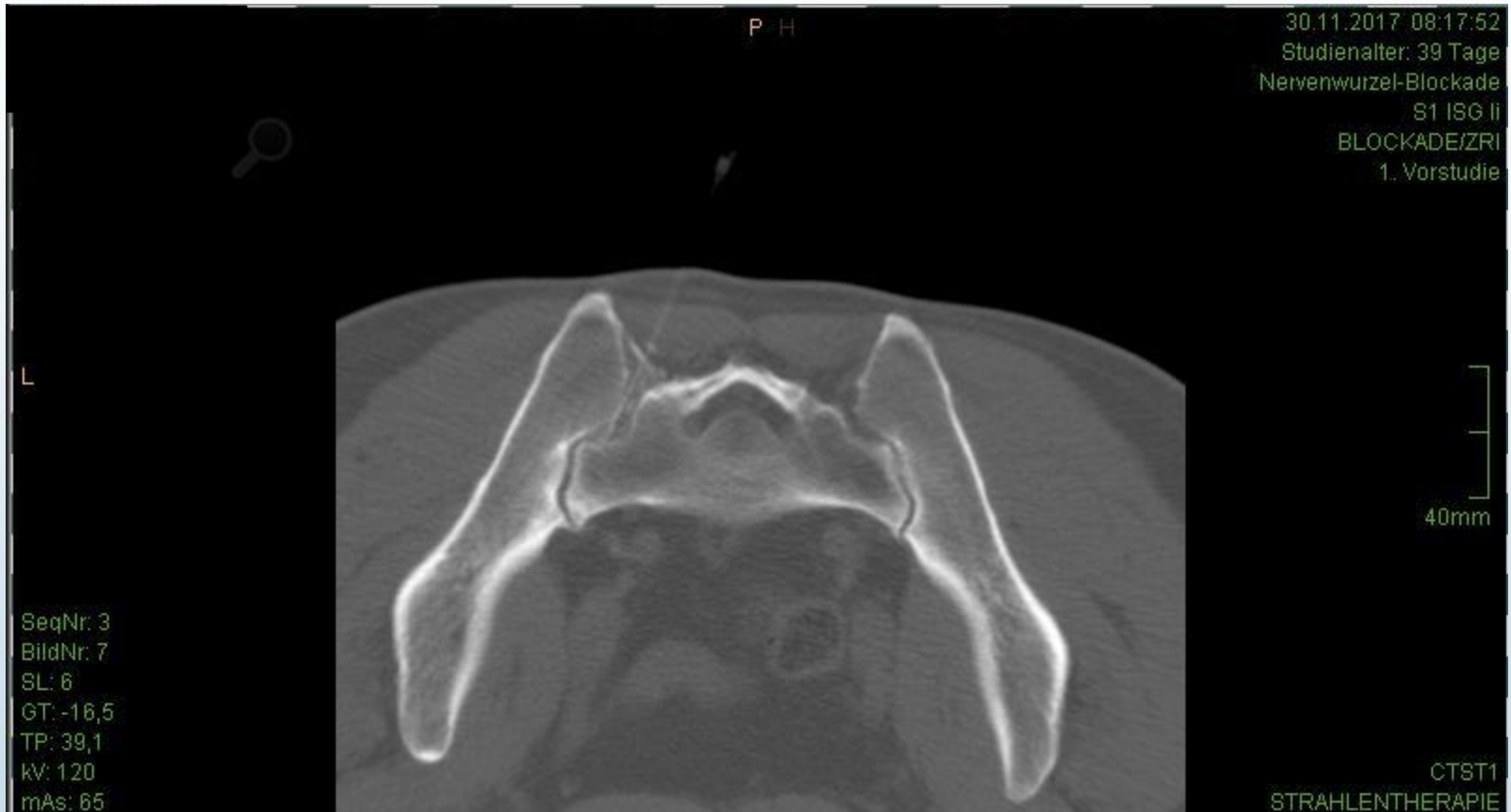


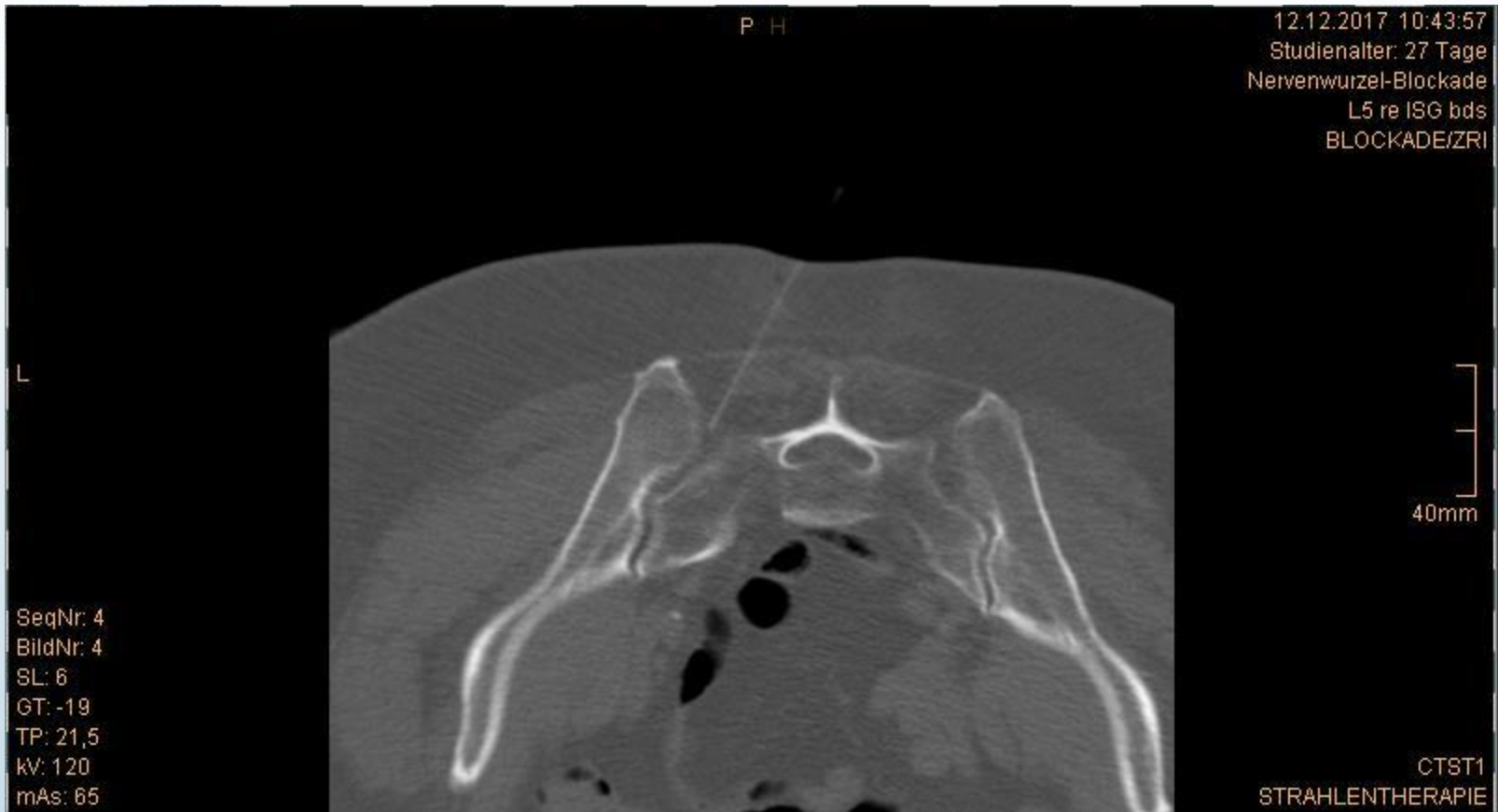
## Iliosakralgelenks-Blockade links

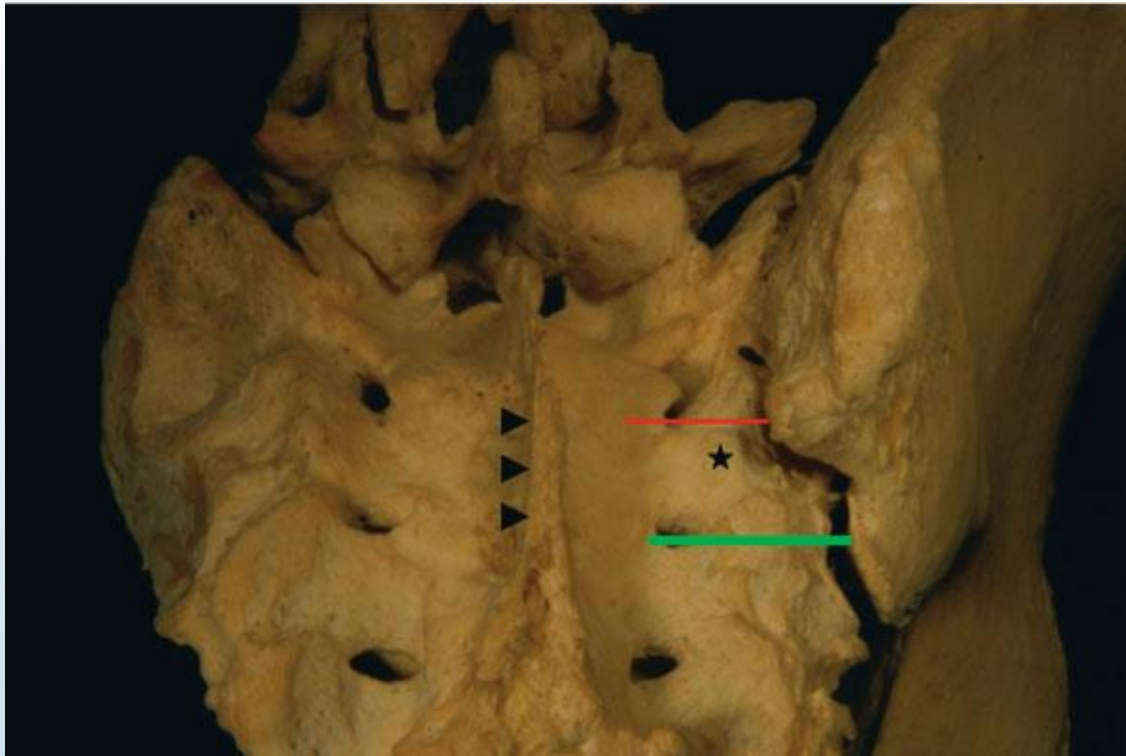




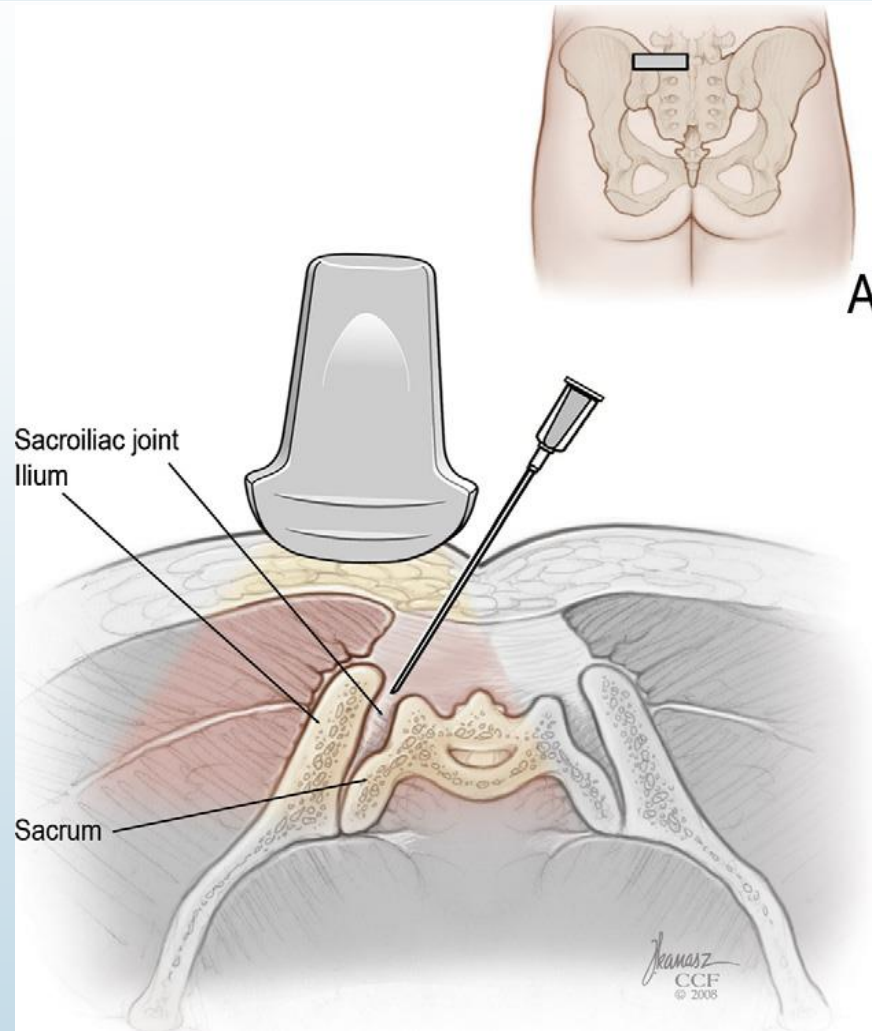








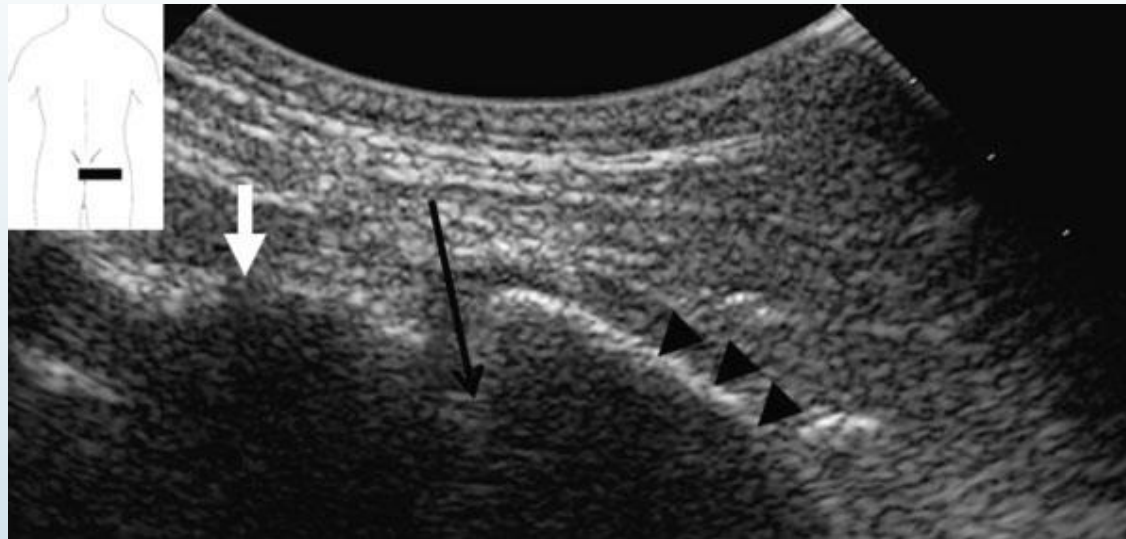
*A.KLAUSER, T. DE ZORDO, G. FEUCHTNER, P. SÖGNER, M. SCHIRMER, J. GRUBER, N. SEPP AND B. MORIGGL; Feasibility of Ultrasound-Guided Sacroiliac Joint Injection Considering Sonoanatomic Landmarks at Two Different Levels in Cadavers and Patients; 2008, American College of Rheumatology, Arthritis & Rheumatism (Arthritis Care & Research) Vol. 59, No. 11, November 15, 2008, 1618–1624*



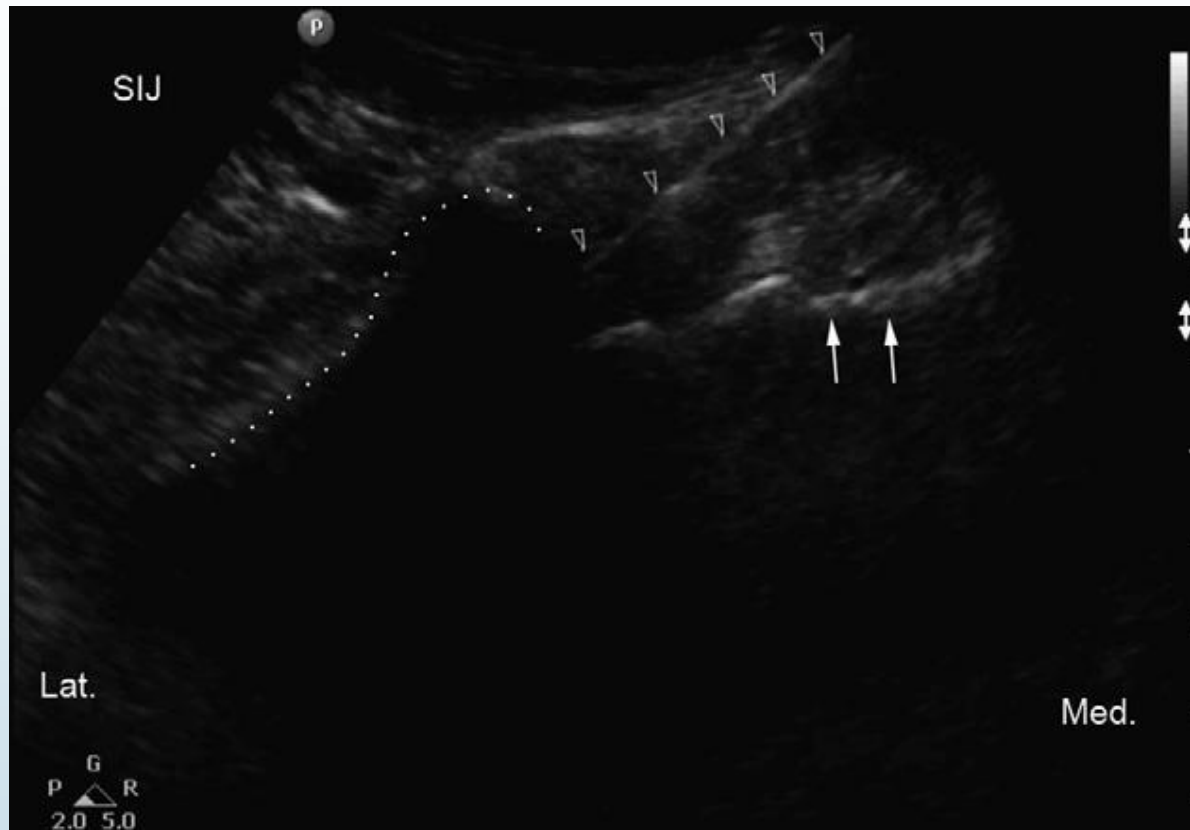- ISG



MORIGL30032018(1).avi

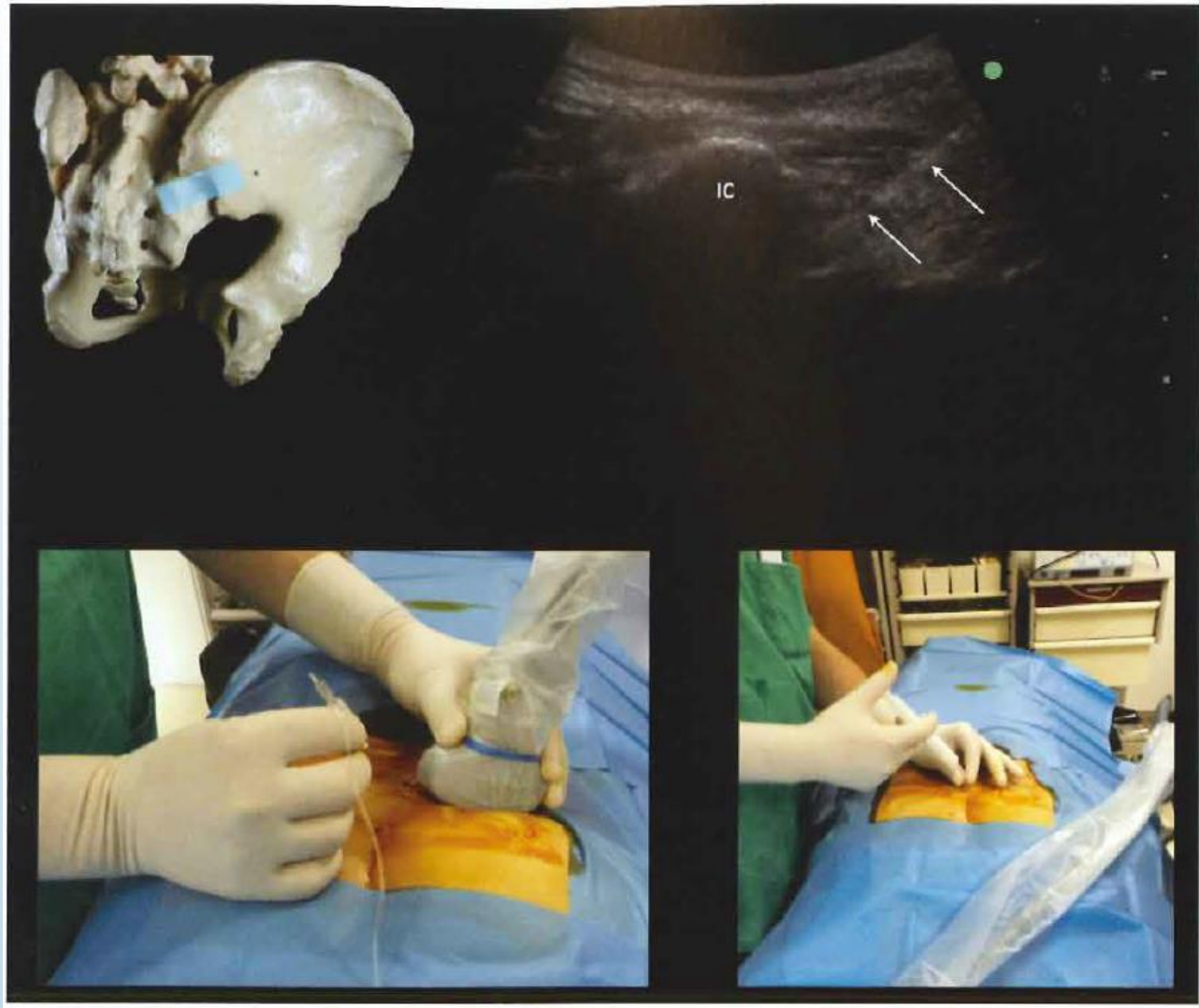

*A.KLAUSER, T. DE ZORDO, G. FEUCHTNER, P. SÖGNER, M. SCHIRMER, J. GRUBER, N. SEPP AND B. MORIGGL; Feasibility of Ultrasound-Guided Sacroiliac Joint Injection Considering Sonoanatomic Landmarks at Two Different Levels in Cadavers and Patients; 2008, American College of Rheumatology, Arthritis & Rheumatism (Arthritis Care & Research) Vol. 59, No. 11, November 15, 2008, 1618–1624*

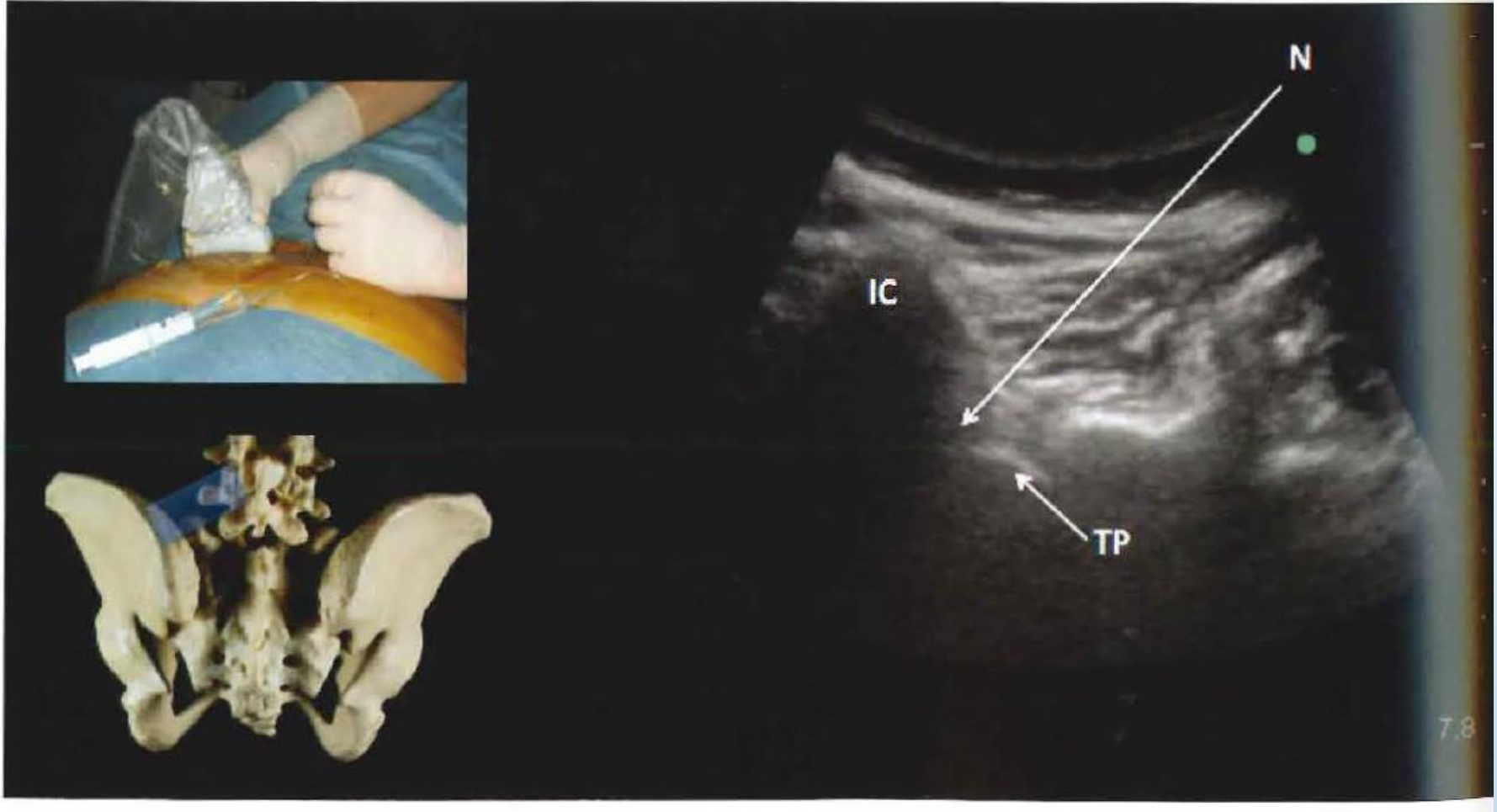


*Klauser A, De Zordo T, Feuchtner G, et al. Feasibility of ultrasound-guided sacroiliac joint injection considering sonoanatomic landmarks at two different levels in cadavers and patients. Arthritis Rheum. 2008;59:1618Y1624*

*Harmon D, O'Sullivan M. Ultrasound-guided sacroiliac joint injection technique. Pain Physician. 2008;11:543Y547*



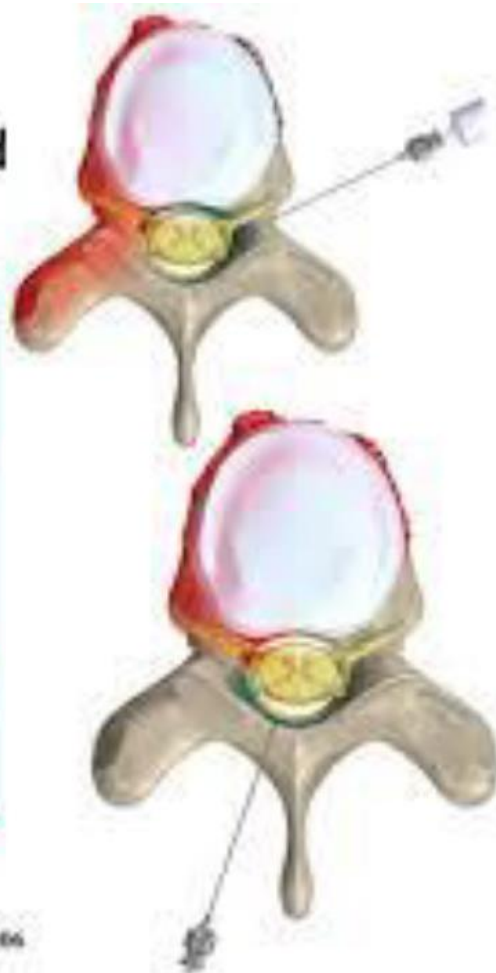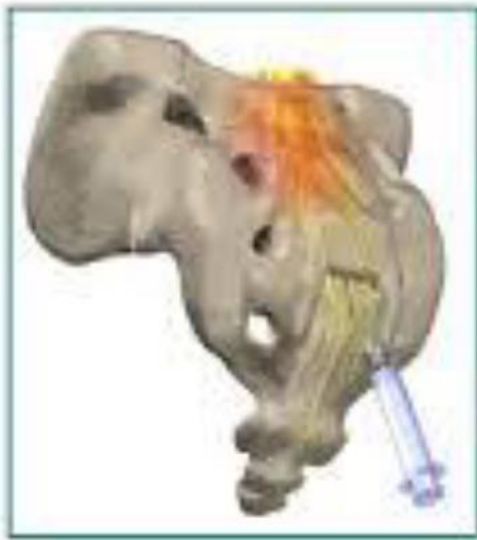Sacroiliac joint puncture. The arrows show the position of the needle. IC: iliac crest



Iliolumbar ligament in-plane puncture technique. IC, indicates iliac crest, TP, transverse process. N, needle direction.

# 3 different routes of ESI

## Epidural Steroid Injections



Transforaminal TF

Interlaminar IL

Caudal



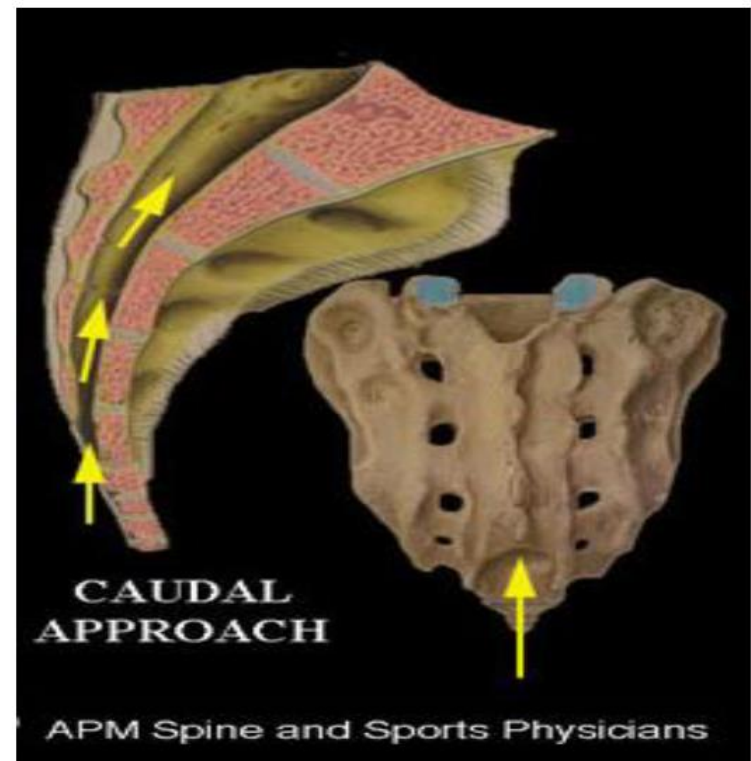
# Caudal epidural

## Advantages:

- Safest and easiest injection
- Decreased incident of dural puncture
- Safety in postsurgical patients
- It can reach multiple levels (spinal stenosis)

## Disadvantage:

- The site of injection might be far from the pathology



## Accessing of epidural space

**Landmark technique** Failure rate 26% (*Stutz Spine 1999,241371-1376*)

Identification

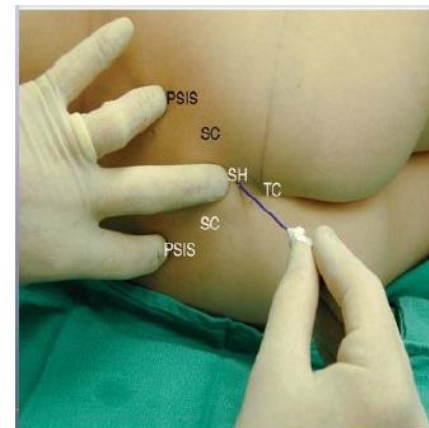
- „Pop sign“
- Aspiration
- „Whoosh“ test (2 ml of air)

has a sensitivity of 94% but a specificity of only 20% with a significant number of false positive results (*Eastwood D, Caudal epidurals: the whoosh test. Anaesthesia 1998; 53: 305–7*)

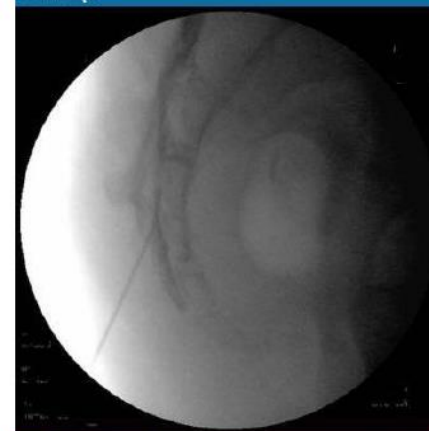**Fluoroscopy** to confirm the location

Real time imaging is advantageous to optimise the outcome

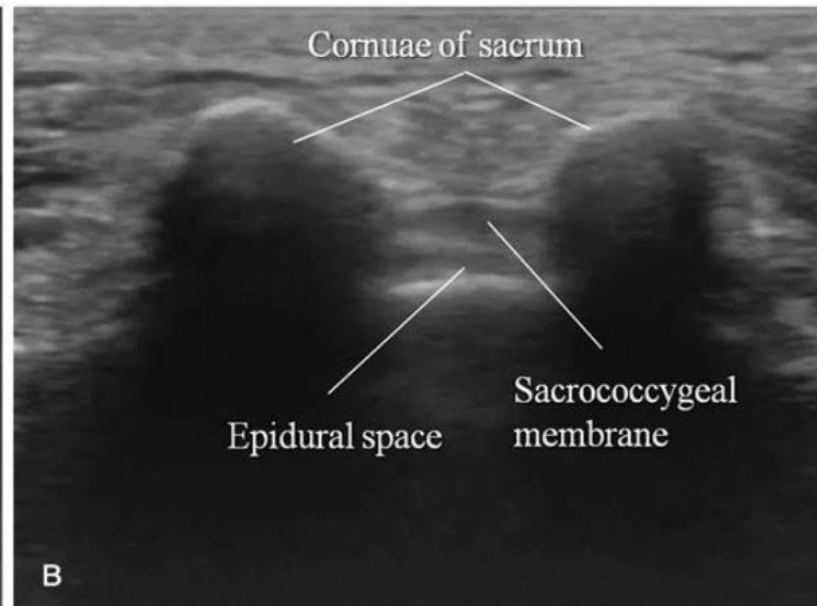
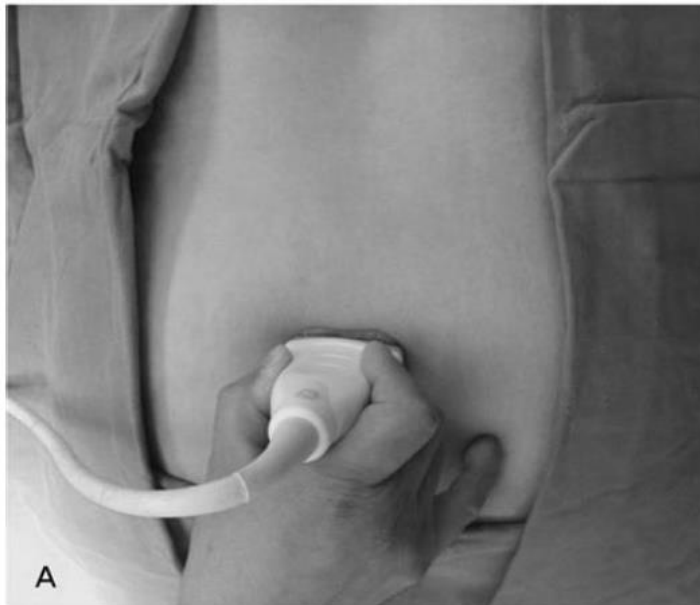- Need for contrast dye
- Limited by costs and space requirements



Medscape



# Epidural Caudal Injection USG-Guided

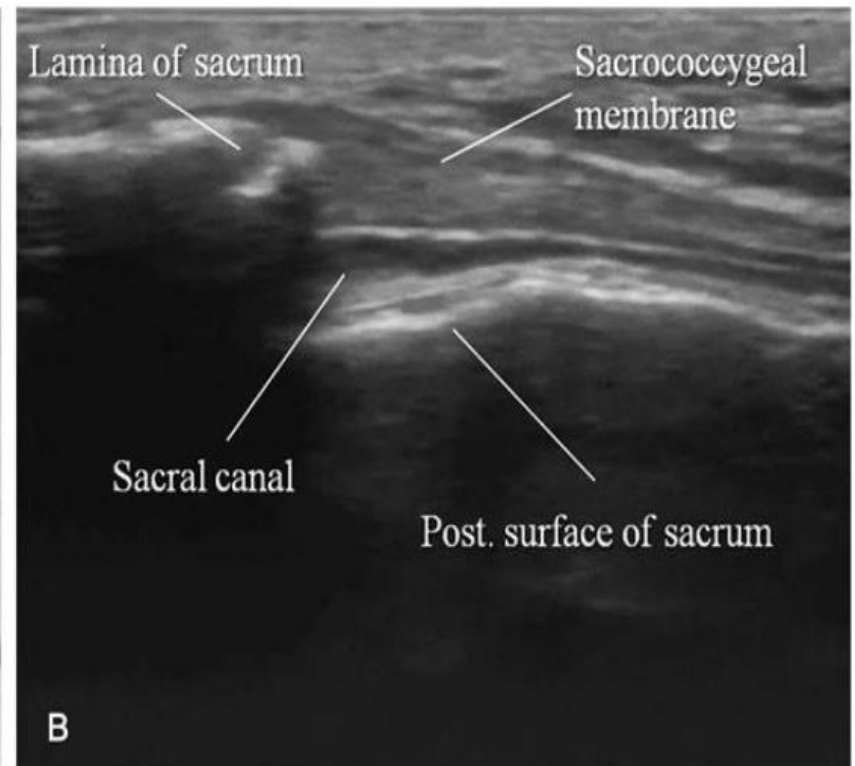
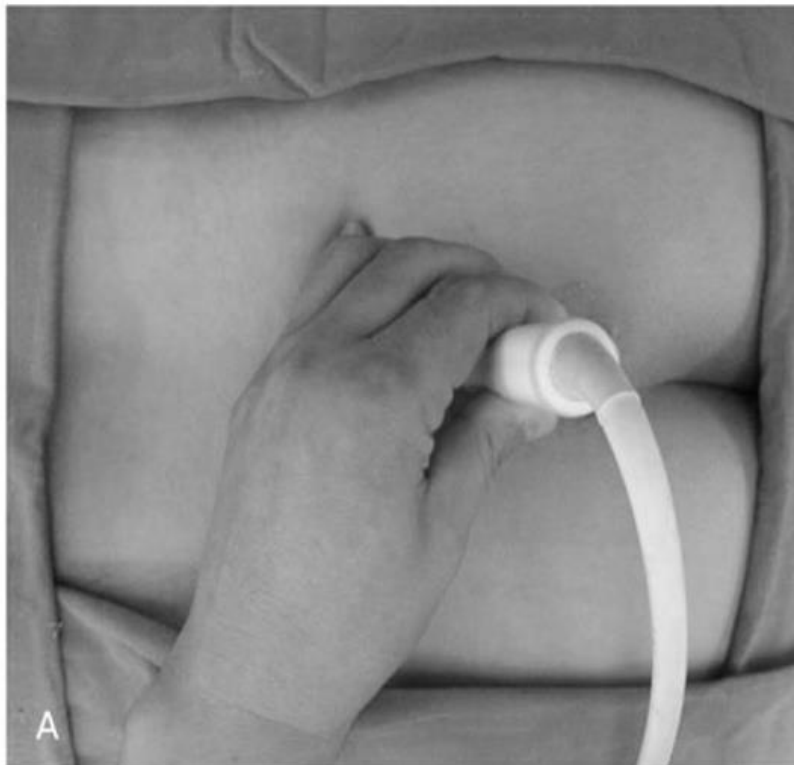

Frog sign

Prone position of the patient

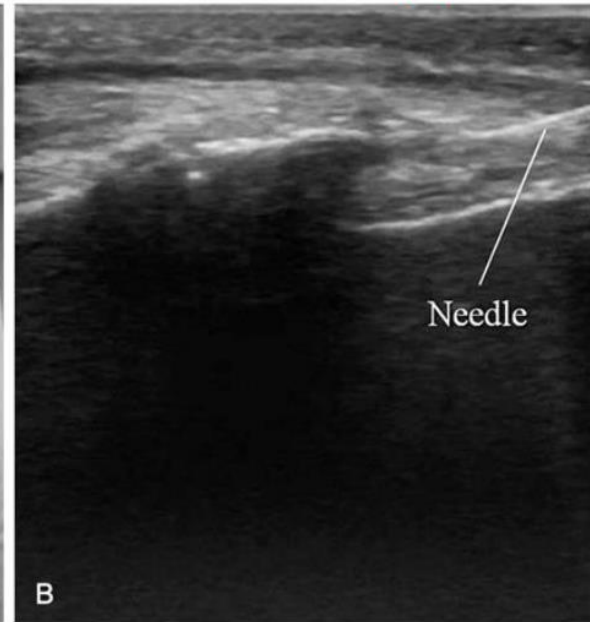
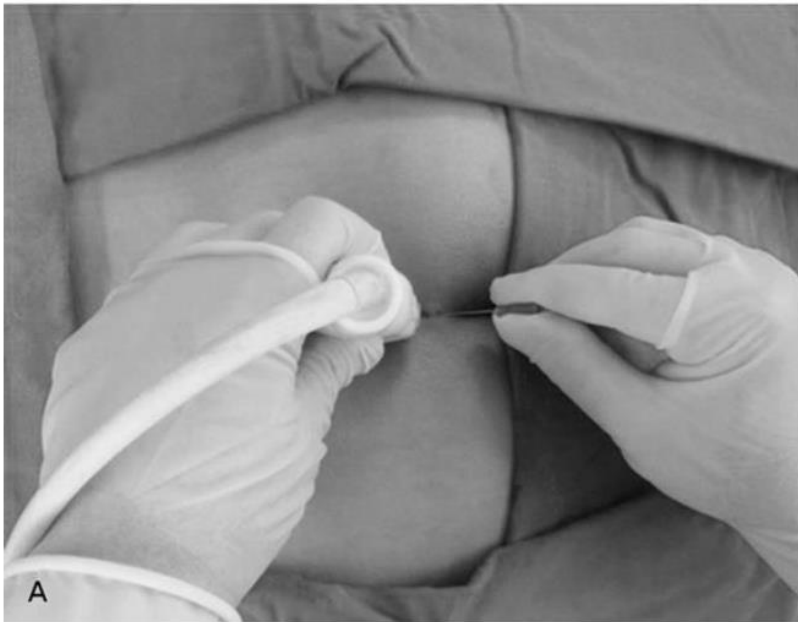- The transducer is placed transversely on the sacral hiatus
- Between the cornua-2 hyperechoic band like structures: Sacrococcygeal lig on the top and dorsal surface of the sacrum at the bottom

# Epidural Caudal USG-Guided Injection



The transducer is rotated 90 degrees to obtain the longitudinal view of sacral hiatus..

# Epidural Caudal Injection USG-Guided



Needle is inserted IP to caudal epidural space under ultrasound guidance..

“Pop” is felt when the ligament is penetrated

After the aspiration the test dose must be given

Needle tip is no longer visible when under the sacrum

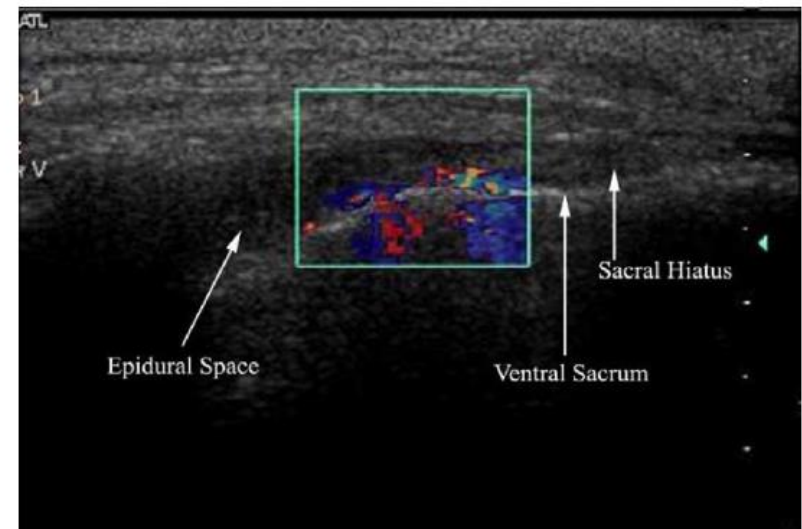
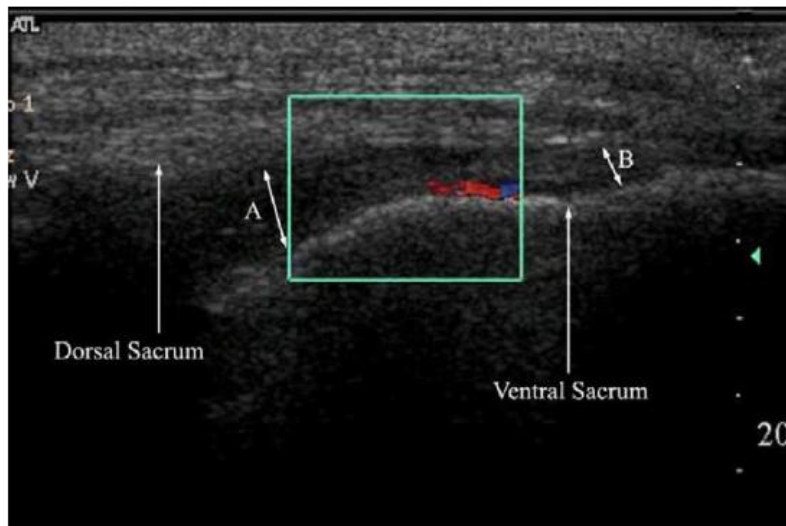
Monitoring of the turbulence in the sacral canal ( colour Doppler)

# US guided Caudal Epidural

- *YOON et al Pain 2005;1 118:210-214*

Use of **colour doppler** to monitor the turbulence in the sacral canal and the cephalad spread of the injectate.

The injection is successful if unidirectional flow- one dominant colour is seen



**Bitte ab sofort bei Epiduralblockaden und CT-gezielten Blockaden anstelle von Urbason „Dexabene“ verwenden.**

**Folgende Dosierung:**

HWS-Blockade:

Statt Urbason 64 mg Dexabene 12 mg

Bucain 0,25 % 2,5 ml + Dexabene 12 mg (3 ml) + 4,5 ml NaCl 0,9 %

LWS-Blockade:

Statt Urbason 64 mg Dexabene 12 mg

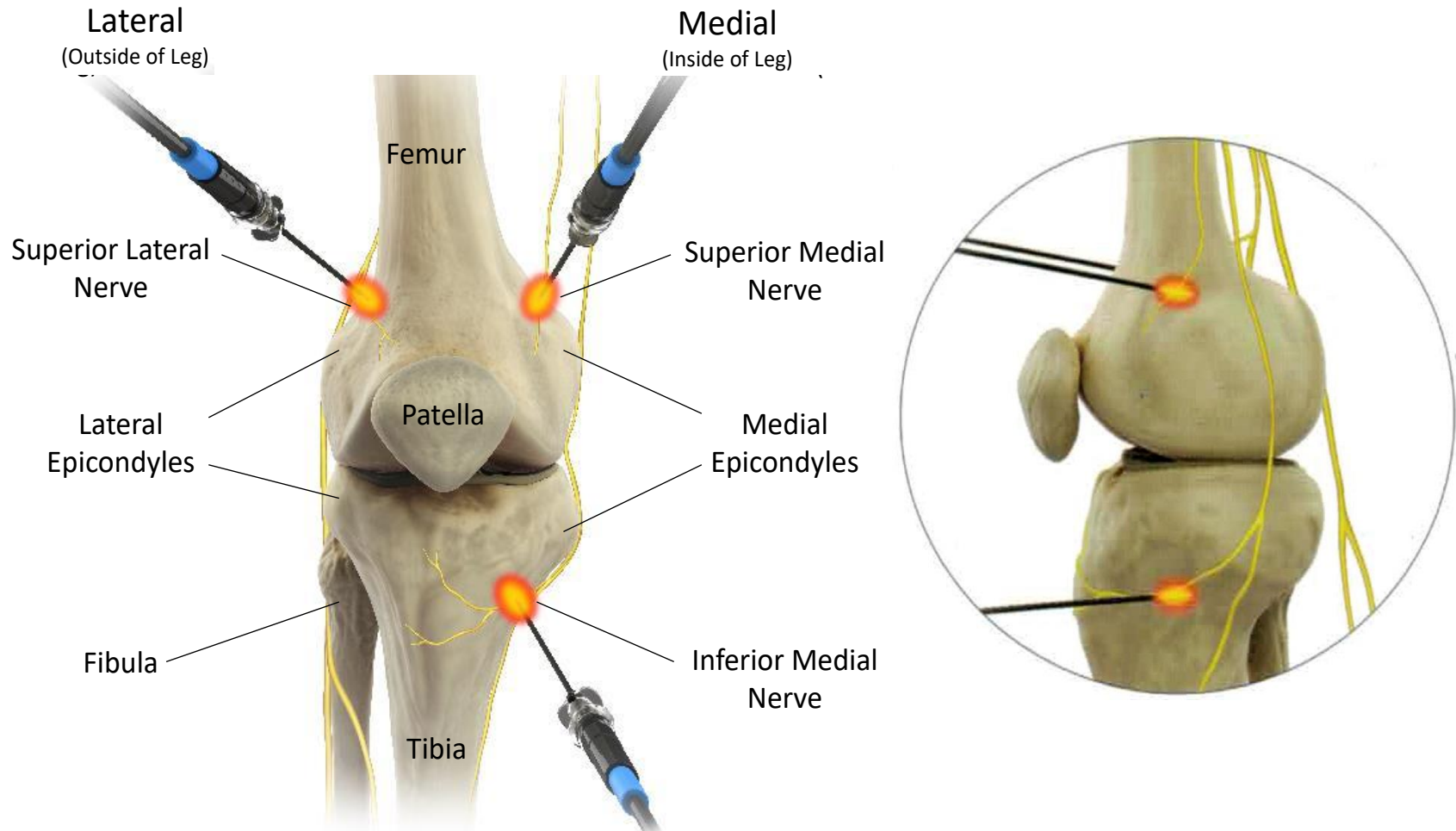
Bucain 0,25 % 5 ml + Dexabene 12 mg (3 ml) + 2 ml NaCl 0,9 %

CT-Blockaden:

Statt Volon-A-KS 40 mg Dexabene 4 mg

Bucain 0,25 % 2,5 ml + Dexabene 4 mg (1 ml) + KM, insgesamt ca. 3,5 ml.

Die restlichen Interventionen können weiterhin mit Urbason durchgeführt werden.





## **Radiofrequenz-Therapie bei chronischen Knieschmerzen**

### **Vorgehensweise**

#### Patientenlagerung:

Rückenlage über Polsterunterlage leicht angewinkelt Knie (  $15^\circ$  )

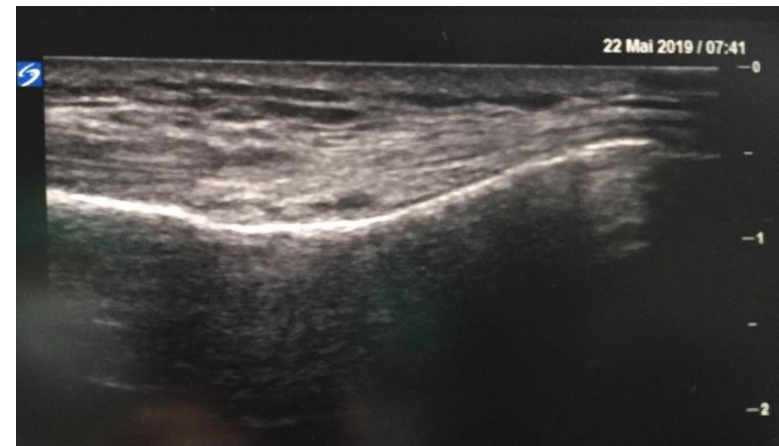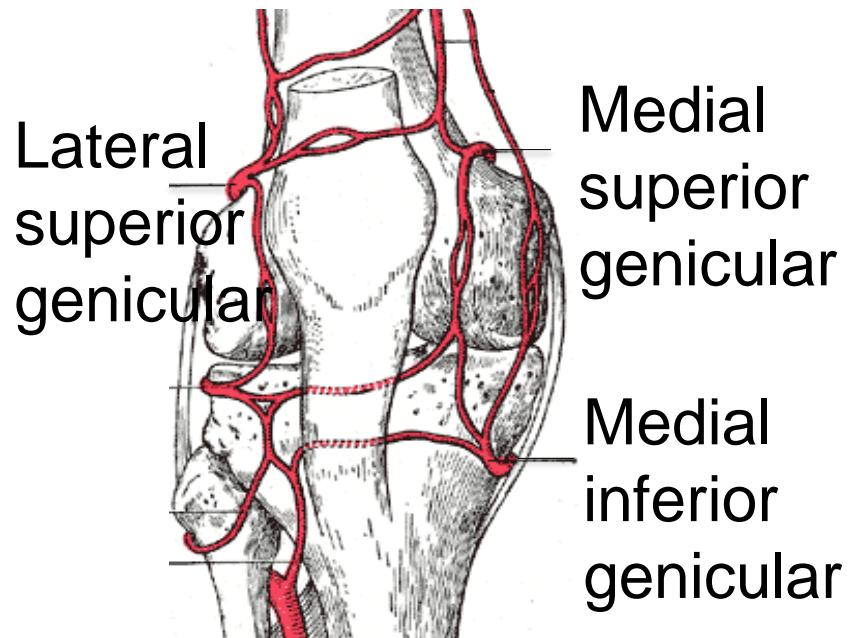
#### Platzierung der großflächigen Neutralelektrode

ca. 10cm oberhalb des zu behandelten Knies.

## Radiofrequenz-Therapie bei chronischen Knieschmerzen

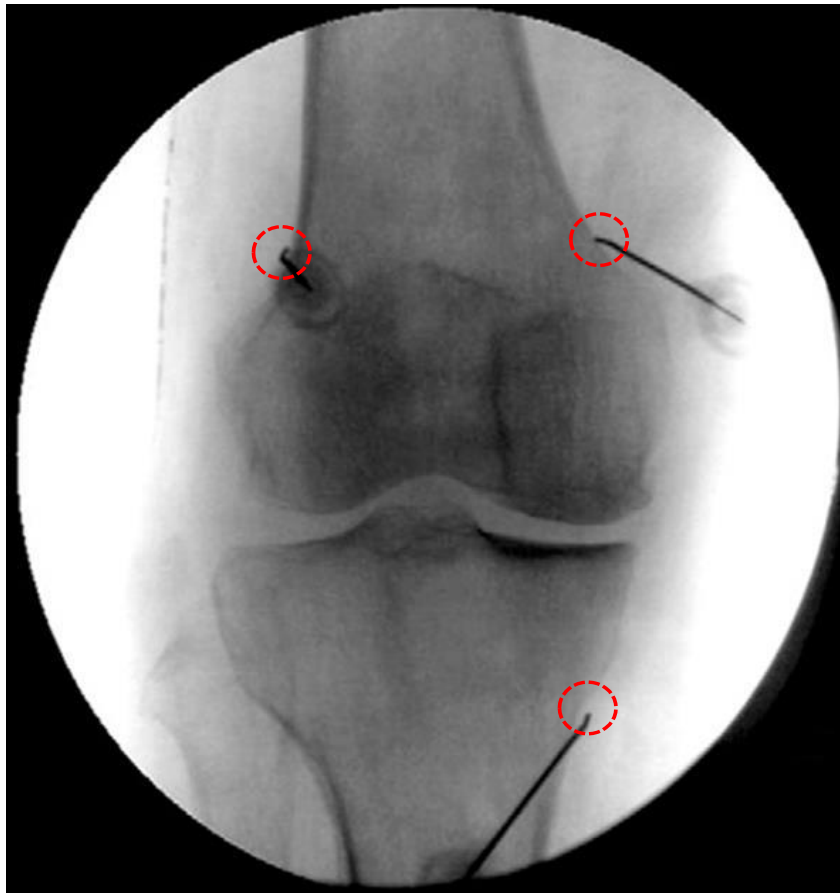
Mittels Ultraschall Darstellung der Genicular - Arterien:

Lateral superior, medial superior und medial inferior.



AP Durchleuchtung: Darstellung des Tibiofemoral-Gelenks so, dass der Gelenkspalt auf beiden Seiten ca. gleich groß ist. Platzierung der RF – Nadeln in AP Darstellung

Lateral  
(Outside of Leg)



Medial  
(Inside of Leg)

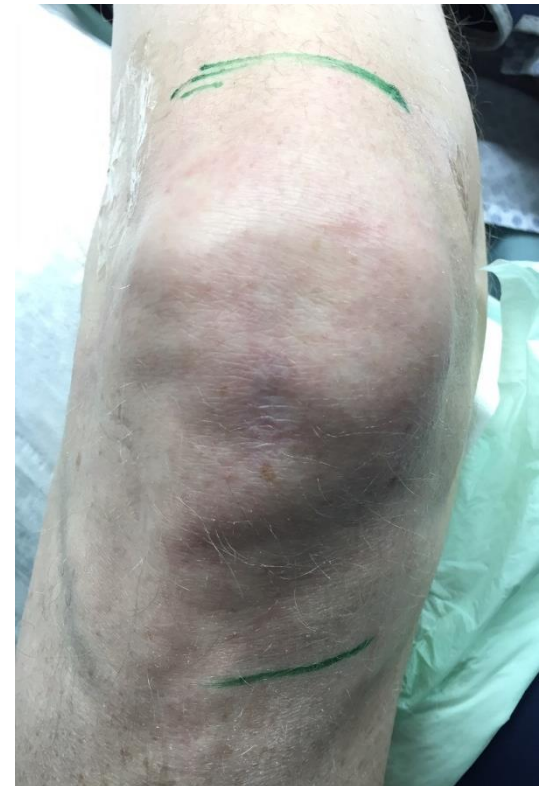## Radiofrequenz-Therapie bei chronischen Knieschmerzen

### Platzierung der Kanüle:

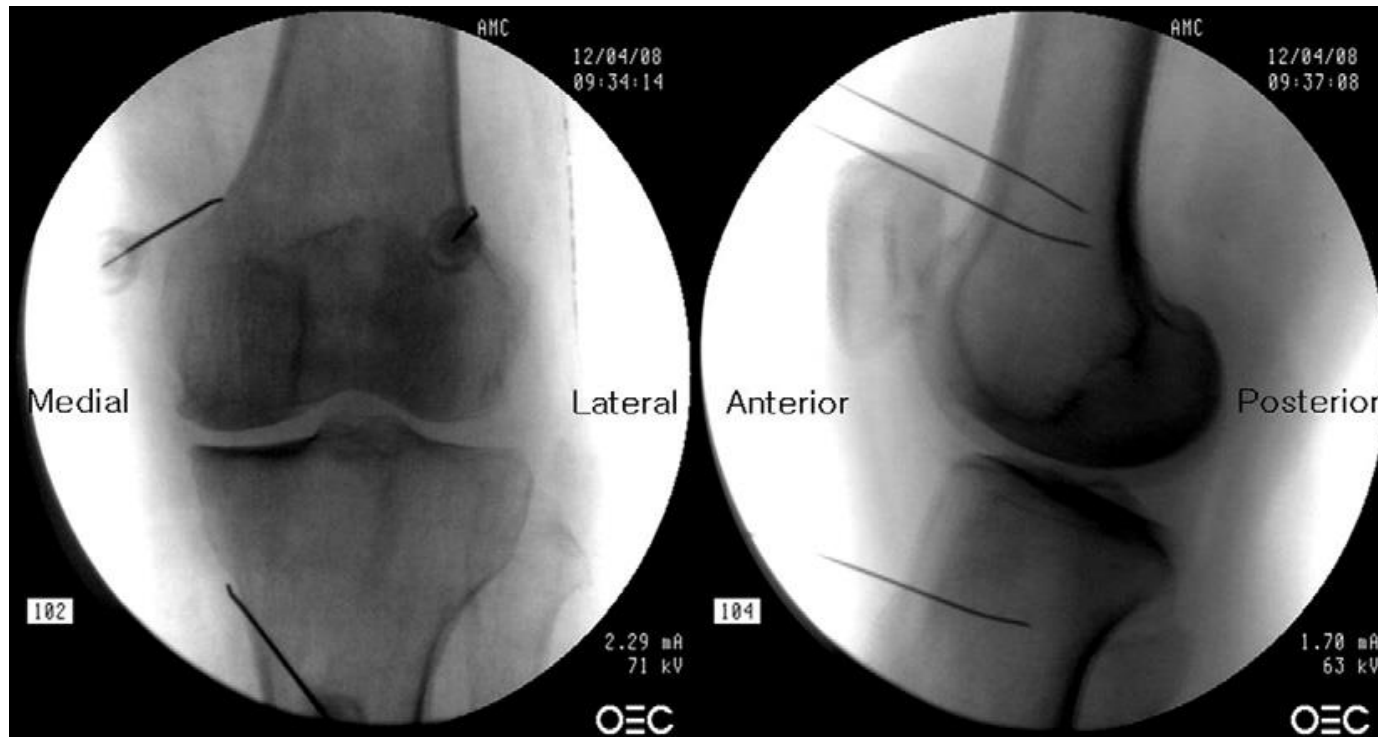Kanüle mit 10cm Länge, 10mm aktiver Spitze und 20-22G (evt. gebogen) an den vorher markierten Punkten unter Röntgenkontrolle Richtung Schnittpunkt zwischen Schaft und Epicondylus bis zum Knochenkontakt vorschieben.

### Unter lateraler Röntgenkontrolle:

Lagebestätigung bzw. Anpassung. Die aktive Spitze sollte sich in der Mitte des Knochens befinden.

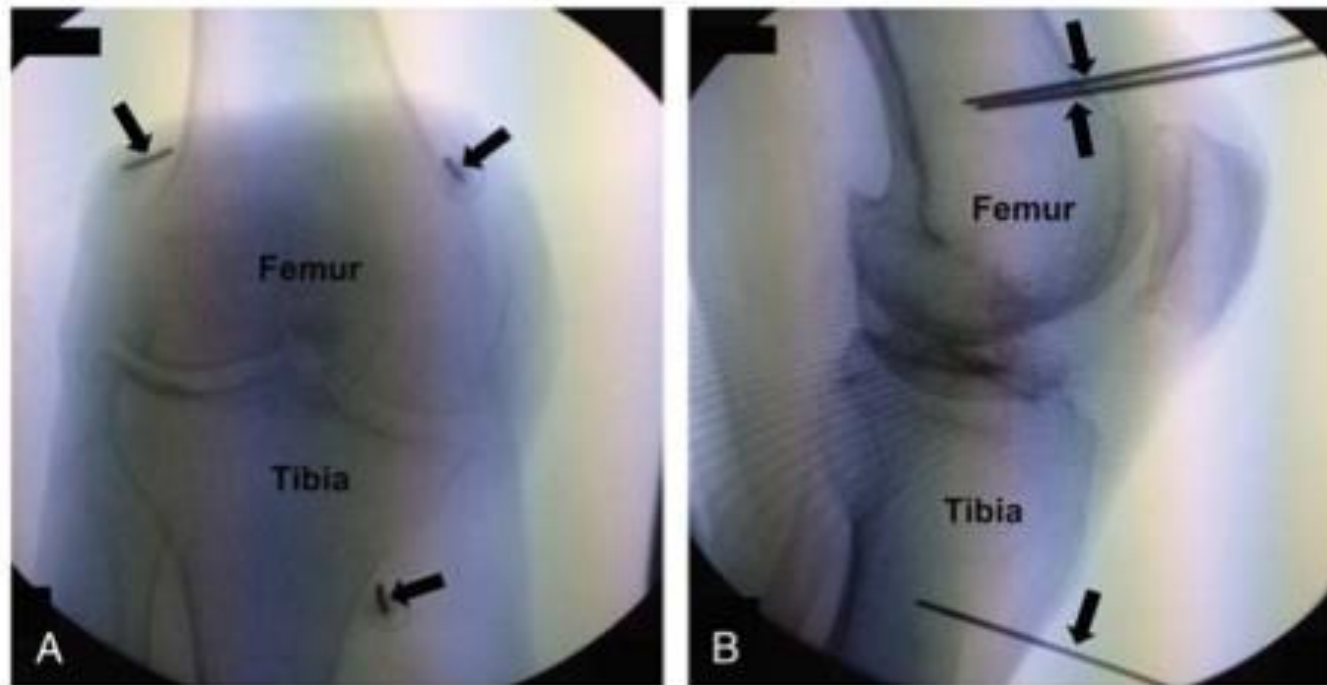


## Platzierung der RF – Nadeln in AP - (A) und lateraler Darstellung (B)



Kamel, Emad Z. "Fluoroscopic guided radiofrequency of genicular nerves for pain alleviation in chronic knee osteoarthritis: a single-blind randomized controlled trial." *Pain physician* 21 (2018): 169-177.

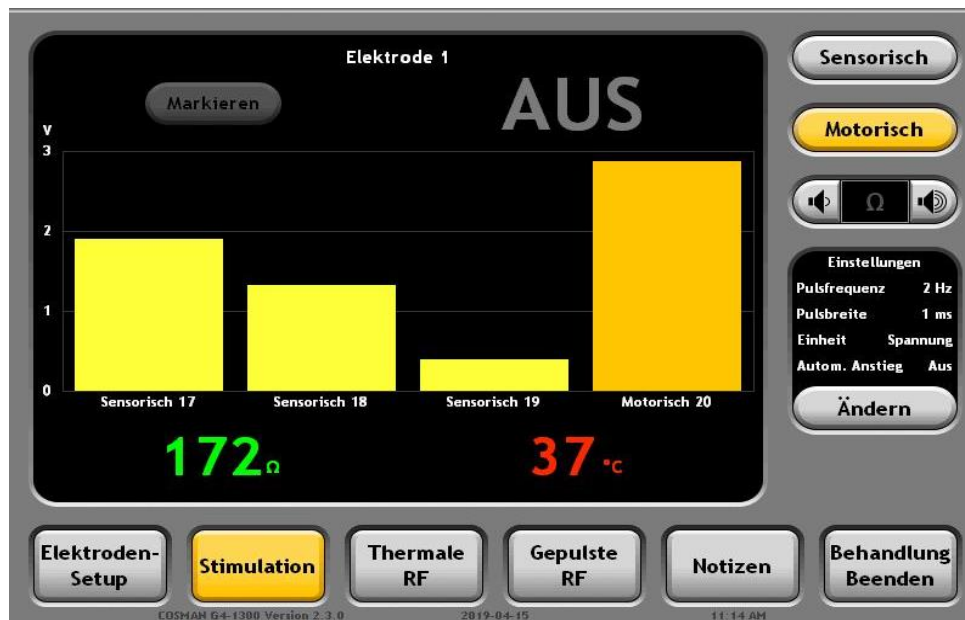
## Platzierung der RF – Nadeln in AP - (A) und lateraler Darstellung (B)



Davis, Tim, et al. "Prospective, multicenter, randomized, crossover clinical trial comparing the safety and effectiveness of cooled radiofrequency ablation with corticosteroid injection in the management of knee pain from osteoarthritis." (2018): 84-91.

## Teststimulation zur korrekten Position der Elektroden (Kanülen)

Sensorische Stimulation: Konkortanter Knieschmerz bei  $<0,5V$  (50Hz) an allen drei Positionen

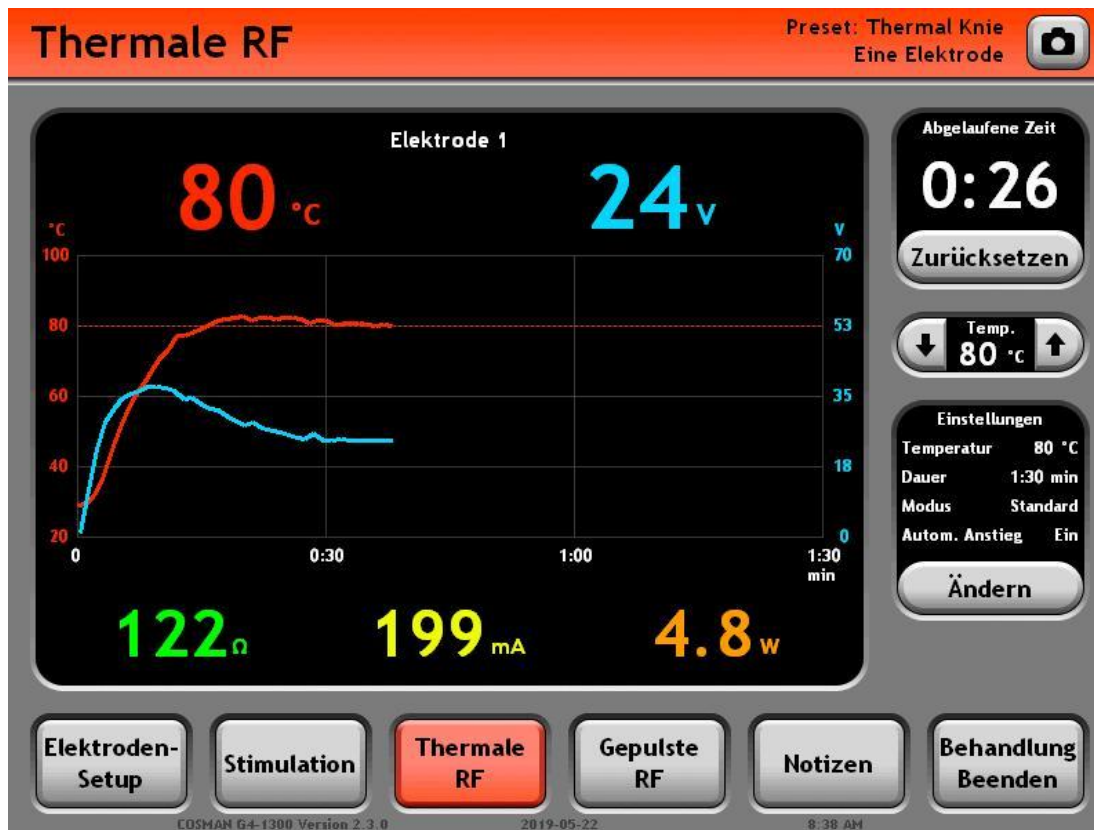


## Teststimulation zum Ausschluss naheliegender motorischer Nerven

Motorische Stimulation: Keine Muskelkontraktionen bei 2,0V (2Hz)

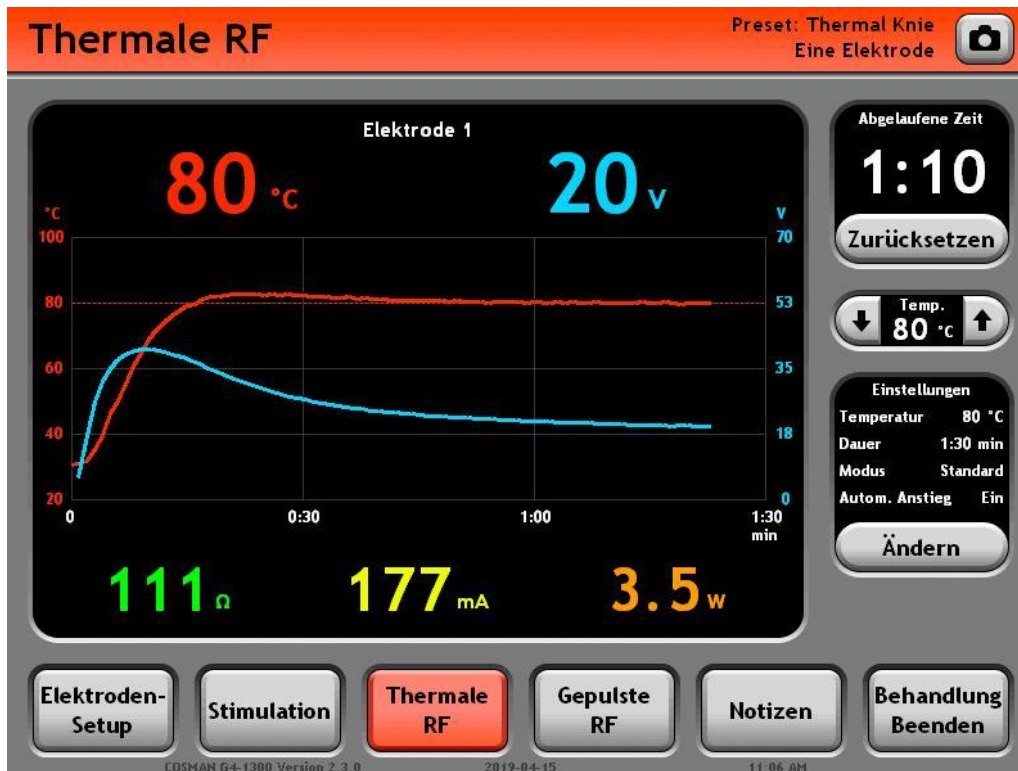
Impedanz wenn möglich  $<300\Omega$

Vor der Läsion Lokalanästhesie: 1 - 2% Lidocain





Impedanz wenn möglich  $<300\Omega$   
Vor der Läsion Lokalanästhesie: 1 - 2% Lidocain



## Abstract

Chronic osteoarthritis (OA) pain of the knee is often not effectively managed with current non-pharmacological or pharmacological treatments. **Radiofrequency (RF) neurotomy is a therapeutic alternative for chronic pain. We investigated whether RF neurotomy applied to articular nerve branches (genicular nerves) was effective in relieving chronic OA knee joint pain.** The study involved 38 elderly patients with (a) severe knee OA pain lasting more than 3 months, (b) positive response to a diagnostic genicular nerve block and (c) no response to conservative treatments. Patients were randomly assigned to receive percutaneous RF genicular neurotomy under fluoroscopic guidance (RF group; n = 19) or the same procedure without effective neurotomy (control group; n = 19). Visual analogue scale (VAS), Oxford knee scores, and global perceived effect on a 7-point scale were measured at baseline and at 1, 4, and 12 weeks post-procedure. VAS scores showed that the RF group had less knee joint pain at 4 (p < 0.001) and 12 (p < 0.001) weeks compared with the control group. Oxford knee scores showed similar findings (p < 0.001). In the RF group, 10/17 (59%), 11/17 (65%) and 10/17 (59%) achieved at least 50% knee pain relief at 1, 4, and 12 weeks, respectively. No patient reported a post-procedure adverse event during the follow-up period. RF neurotomy of genicular nerves leads to significant pain reduction and functional improvement in a subset of elderly chronic knee OA pain, and thus may be an effective treatment in such cases. Further trials with larger sample size and longer follow-up are warranted.

**Table 1**

Baseline characteristics of patients with chronic knee pain randomly assigned to receive Radiofrequency (RF) neurotomy or lidocaine (control).

Characteristics	Control (n = 18)	RF (n = 17)	P-values
Age (yrs), mean ± SD	66.5 ± 4.8	67.9 ± 7.1	0.559
Sex (M/F)	3/15	2/15	1.0
Height (cm), mean ± SD	155.3 ± 7.5	151.9 ± 6.2	0.182
Weight (kg), mean ± SD	63.1 ± 5.1	61.6 ± 9.0	0.204
Body mass index, mean ± SD	26.5 ± 2.1	26.2 ± 3.3	0.567
Duration (years), mean ± SD	7.4 ± 4.0	6.3 ± 3.9	0.404
Treatment sites (right/left)	10/8	8/9	0.740
Visual analogue pain scale (0–100 mm), mean ± SD	77.2 ± 7.5	78.2 ± 13.8	0.942
Oxford knee score (12–60 points), mean ± SD	39.2 ± 4.4	39.8 ± 6.5	0.486
Radiographic disease severity (Kellgren–Lawrence grade)			
2	4	3	
3	7	8	0.879
4	7	6	

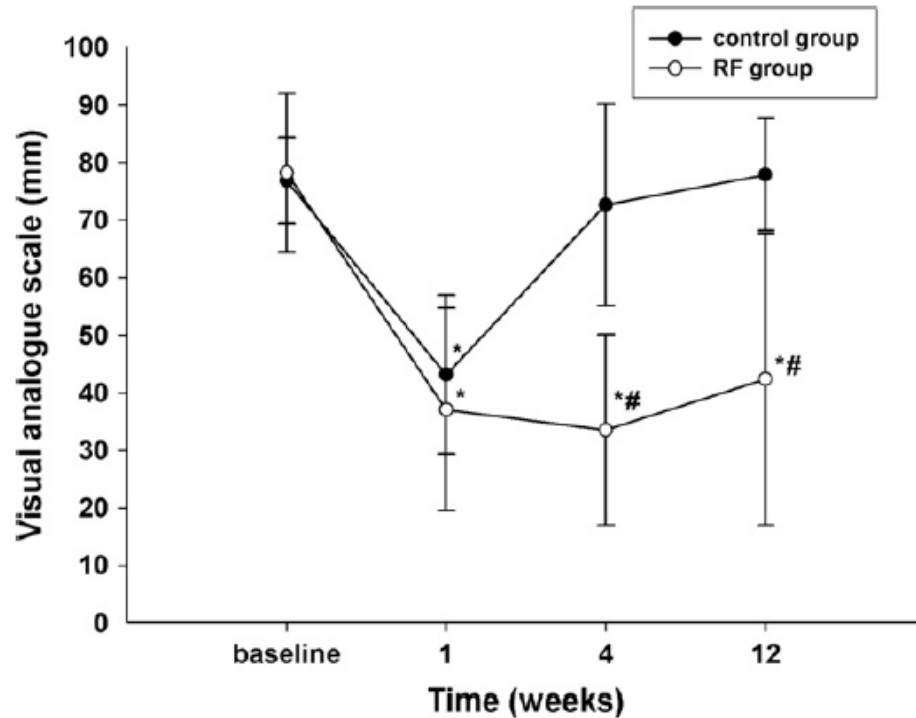
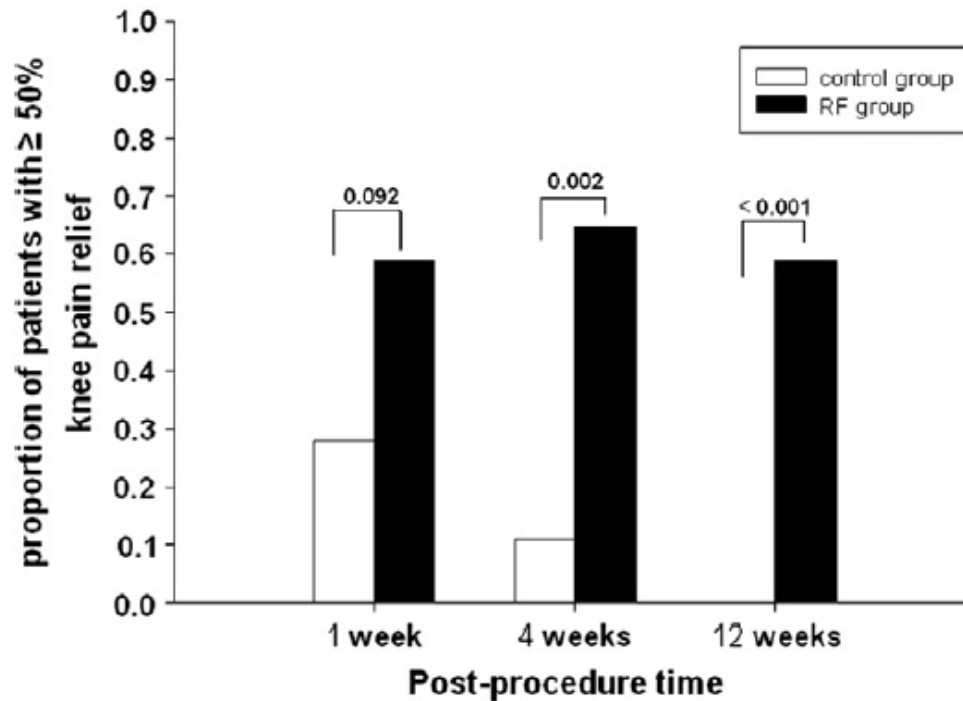


Fig. 3. Visual analogue scale pain scores in patients receiving radiofrequency (RF) neurotomy or lidocaine (control). Values represent mean and standard deviation. \* $p < 0.05$  vs. baseline. # $p < 0.05$  vs. control group.



**Fig. 4.** Proportion of patients achieving at least 50% knee pain relief at follow-up. At 12 weeks post-procedure,  $\geq 50\%$  knee pain relief was observed in 10 radiofrequency (RF) neurotomy patients (59%) and in no control patients.

## RESULTS:

At 12 months, 65% of the original CRFA group had pain reduction  $\geq 50\%$ , and the mean overall drop was 4.3 points ( $p < 0.0001$ ) on the numeric rating scale. Seventy-five per cent reported 'improved' effects. The cross-over group demonstrated improvements in pain and functional capacity ( $p < 0.0001$ ). No unanticipated adverse events occurred.

## CONCLUSIONS:

**This study demonstrates that analgesia following CRFA for OA knee pain could last for at least 12 months and could rescue patients who continue to experience intolerable discomfort following IAS.**

## CLINICAL TRIAL REGISTRATION

:

The ClinicalTrials.gov registration number for this study is [NCT02343003](https://clinicaltrials.gov/ct2/show/study/NCT02343003).

## **Results:**

We identified nine relevant clinical trials, which included 592 patients, evaluating knee RFA for osteoarthritis and persistent postsurgical pain. These included one randomized, placebo-controlled trial, one randomized controlled trial evaluating RFA as add-on therapy, four comparative-effectiveness studies, two randomized trials comparing different techniques and treatment paradigms, and one non-randomized, controlled trial. The results of these studies demonstrate significant benefit for both reduction and functional improvement lasting between 3 and 12 months, with questionable utility for prognostic blocks. There was considerable variation in the described neuroanatomy, neural targets, radiofrequency technique, and selection criteria.

## **Conclusion:**

**RFA of the knee appears to be a viable and effective treatment option, providing significant benefit to well-selected patients lasting at least 3 months. More research is needed to better identify neural targets, refine selection criteria to include the use of prognostic blocks, optimize treatment parameters, and better elucidate relative effectiveness compared to other treatments.**

# Conclusions

Ultrasound is a valuable tool for imaging soft-tissue structures and bony surfaces, guiding needle advancement and confirming the spread of injectate around the target without exposing health care providers and patients to the risks of radiation. There is a rapidly growing interest in USPM as evidenced by the surging number of publications in the last few years. However, most of these publications are small feasibility studies. Currently, we have only weak evidence that US is superior to CT in lumbar facet intraarticular injections (1 small RCT, level 1b). Although we do have a few reports suggesting that US-guided cervical injections have advantages over fluoroscopy-guided approaches (especially in stellate ganglion and cervical nerve root blocks), there are no RCT-driven data to support this.

**Future research directions should focus on the cervical spine, peripheral pain blocks (intercostal nerve, suprascapular nerve etc), and muscle and joint injections as US looks promising in these areas. We are in need for more studies to report on the efficacy and safety of US-guided techniques.**



## KEYWORDS

- Epidural • Facet • Interventional spine • Interventional pain • Pain management
- Sonography • Spine injections • Ultrasonography

## KEY POINTS

- Ultrasound (US) has become a more common imaging modality for spinal interventions.
- US has some advantages and disadvantages compared with fluoroscopy and other imaging modalities.
- Most typical spinal pain procedures described under fluoroscopy have also been described with US guidance.
- Although there are multiple studies demonstrating the accuracy of US-guided spine procedures using cadaveric dissections as well as comparing their accuracy to procedures with CT or fluoroscopic guidance, there are no large studies comparing the safety or efficacy of US-guided spinal interventions to CT or fluoroscopic guidance.
- Some spinal interventions where the spinal vascular supply may be at risk may still benefit from fluoroscopic or CT-confirmed contrast-controlled verification.

**Table 2. Summary of Evidence Scores and Implications for Recommendation**

Score	Description	Implication
1 A +	Effectiveness demonstrated in various RCTs of good quality. The benefits clearly outweigh risk and burdens	Positive recommendation
1 B +	One RCT or more RCTs with methodological weaknesses, demonstrate effectiveness. The benefits clearly outweigh risk and burdens	
2 B +	One or more RCTs with methodological weaknesses, demonstrate effectiveness. Benefits closely balanced with risk and burdens	
2 B ±	Multiple RCTs, with methodological weaknesses, yield contradictory results better or worse than the control treatment. Benefits closely balanced with risk and burdens, or uncertainty in the estimates of benefits, risk and burdens.	Considered, preferably study-related
2 C +	Effectiveness only demonstrated in observational studies. Given that there is no conclusive evidence of the effect, benefits closely balanced with risk and burdens	
0	There is no literature or there are case reports available, but these are insufficient to prove effectiveness and/or safety. These treatments should only be applied in relation to studies.	Only study-related
2 C -	Observational studies indicate no or too short-lived effectiveness. Given that there is no positive clinical effect, risk and burdens outweigh the benefit	Negative recommendation
2 B -	One or more RCTs with methodological weaknesses, or large observational studies that do not indicate any superiority to the control treatment. Given that there is no positive clinical effect, risk and burdens outweigh the benefit	

# Summary of the Recommendations

<b>Trigeminal neuralgia</b>			
Microvascular decompression		Very low	Very weak
Stereotactic radiosurgery		Very low	Very weak
Radiofrequency treatment of the ganglion Gasserii	2 B+	Low	Weak
Pulsed radiofrequency	2 B-	Very low	Very weak
<b>Cluster headache</b>			
Uni- or bilateral injection of nervus occipitalis		Not graded	Very weak
Radiofrequency treatment of ganglion pterygopalatinum	2 C+	Very low	Weak
Stimulation of ganglion pterygopalatinum		Very low	Very weak
Occipital nerve stimulation	2 C+	Low	Very weak
<b>Persistent idiopathic facial pain</b>			
Pulsed radiofrequency of ganglion pterygopalatinum	2 C+	Very low	Very weak
Radiofrequency of ganglion pterygopalatinum		Very low	Very weak
<b>Cervical radicular pain</b>			
Interlaminar epidural corticosteroid administration	2 B+	Moderate	Weak
Transforaminal epidural preservative-free dexamethasone	2 B- (not dexamethasone)	Very low	Very weak
Pulsed radiofrequency treatment adjacent to de DRG	1 B+	Moderate	Moderate
Radiofrequency treatment adjacent to de DRG	2 B+	Moderate	Weak
Spinal cord stimulation	0	Not graded	Very weak
<b>Cervical facet joint pain</b>			
Intra-articular corticosteroid administration	0	Low	Weak against
Therapeutic (repetitive) cervical medial branch injections of local anesthetic with or without corticosteroid	2 B+	Moderate	Weak
Radiofrequency treatment of ramus medialis of the ramus dorsalis	2 C+	Low	Weak
<b>Cervicogenic headache</b>			
Injection of the nervus occipitalis major with local anesthetic with or without steroid	1 B+	Moderate	Weak
Injection of atlanto-axial joint with local anesthetic with or without steroid	2 C-	Not graded	Weak against
Radiofrequency treatment of cervical ramus medialis	2 B+/-	Very low	Very weak
Pulsed radiofrequency treatment of nervus occipitalis major		Low	Weak
Pulsed radiofrequency treatment of atlanto-axial joint		Not graded	Very weak
Pulsed radiofrequency of cervical DRG (C2-C3)	0		
<b>Whiplash-associated disorder</b>			
Botulinum toxin injections	2 B-	Moderate	Moderate against
Radiofrequency treatment of cervical ramus medialis of the ramus dorsalis	2 B+	Low	Moderate
Intra-articular corticosteroid injections	2 C-	Very low	Very weak against
<b>Occipital neuralgia</b>			
A single infiltration of the nervi occipitales with local anesthetic and corticosteroids	2 C+	Very low	Very weak
Pulsed radiofrequency of the nervi occipitales	2 C+	Very low	Weak
Pulsed radiofrequency adjacent to the DRG	0		
Peripheral nerve stimulation	2 C+	Very low	Very weak
Botulinum toxin injections	2 C+/-	Very low	Very weak
Stimulation of the nervi occipitales	2 C+	Very low	Very weak
<b>Thoracic radicular pain syndrome</b>			
Intercostal nerve blocks	0	Not graded	Not applicable
(Pulsed) radiofrequency of thoracic DRG	2 C+	Low	Weak
<b>Pain originating from the thoracic facet joint</b>			
Addition of corticosteroids to local anesthetic for thoracic medial branch blocks		High	Moderate against
<b>Lumbosacral radicular pain</b>			
Epidural corticosteroid administration (interlaminar, transforaminal contained herniation, and transforaminal extruded herniation)		Moderate	Weak
Epidural TNF- $\alpha$ inhibitors		Low	Weak against
Radiofrequency treatment adjacent to lumbar DRG	2 A-	Moderate	Moderate against
Pulsed radiofrequency treatment adjacent to lumbar DRG	2 C+	Moderate	Moderate
<b>Failed back surgery syndrome</b>			
Adhesiolysis	2 B+/-	Very low	Very weak
Epiduroscopy	2 B +/-	Moderate	Weak
Spinal cord stimulation (tonic)	2 A+	Moderate	Moderate
Spinal cord stimulation (HF-10)		Not graded	Moderate
Subcutaneous stimulation as add-on to spinal cord stimulation		Not graded	Very weak
<b>Pain originating from the lumbar facet joints</b>			
Intra-articular injection of local anesthetic with or without corticosteroid	2 B+/-	Low	Very weak
Radiofrequency treatment of the ramus medialis of the ramus dorsalis	1 B+	Low	Weak
Pulsed radiofrequency treatment of ramus medialis of the ramus dorsalis		Low	Very weak against

**Huygen F. et al.;**  
**„Evidence-Based**  
**Interventional Pain**  
**Medicine**  
**According to**  
**Clinical**  
**Diagnoses“:**  
**Update 2018: Pain**  
**Practice, Volume**  
**19, Issue 6, 2019**  
**664-675.**

(Continued)

Treatment	Recommendations in 2010†	GRADE Level of Evidence in 2015	Recommendations in 2018
Spinal canal stenosis			
Spinal cord stimulation		Very low	Very weak
Pulsed radiofrequency treatment adjacent to DRG		Moderate	Moderate
Epidural local injections (without steroids)		Low	Weak
Epidural corticosteroid injections		High	Moderate against
Sacroiliac joint pain			
Intra-articular corticosteroid injections	1 B+	Low	Weak
Radiofrequency treatment of rami dorsalis and lateralis (palisade)	2 C+	Very low	Very weak
Radiofrequency treatment of rami dorsalis and lateralis (palisade) SIJ pain due to ankylosing spondylitis		Moderate	Moderate
Radiofrequency treatment of rami dorsalis and lateralis (simplicity)		Not graded	Moderate against
Pulsed radiofrequency treatment of rami dorsalis and lateralis	2 C+	Not graded	Very weak
Radiofrequency treatment of ramus dorsalis at L4-L5 and cooled radiofrequency of the ramus lateralis	2 B+	Low	Weak
Cooled radiofrequency treatment of ramus dorsalis at L4-L5 and ramus lateralis		Moderate	Moderate
Discogenic pain			
Intradiscal methylene blue injection		Moderate	Weak
Intradiscal corticosteroid injection	2 B--	Low	Weak against
Intradiscal radiofrequency treatment	2 B+/-	Low	Weak against
Intradiscal electrothermal therapy		Low	Weak
Intradiscal pulsed radiofrequency treatment	2 B+/-	Very low	Very weak
Intradiscal biacuplasty	0	Moderate	Moderate
Distrode	0		
Radiofrequency treatment of ramus communicans	2 B +	Very low	Very weak against
Complex regional pain syndrome			
Sympathetic blocks with local anesthetics	2 B+	Moderate	Moderate against
Thoracic block (T2-T3) with ropivacaine and triamcinolone		Low	Weak
IV regional blocks with guanethidine	2 A--	Moderate	Moderate against
Spinal cord stimulation	2 B+	Moderate	Moderate
DRG stimulation (for lower extremity CRPS)		Moderate	Moderate
Peripheral nerve stimulation	2 C+	Very low	Very weak
Low-dose IV ketamine		Moderate	Weak
Herpes zoster and postherpetic neuralgia			
Acute phase: epidural injection of corticosteroid with local anesthetics	2 B+	Moderate	Moderate
Acute phase: paravertebral injections of corticosteroids with local anesthetics		Moderate	Moderate
Acute phase: repeated epidural injections of corticosteroid with local anesthetics and epinephrine		Moderate	Weak
Acute phase: stellate ganglion block	2 C+	Low	Weak
Treatment of postherpetic neuralgia: epidural corticosteroid injections or combined therapy with intrathecal midazolam	0	Low	Weak
Treatment of postherpetic neuralgia: sympathetic nerve block	2 C+	Very low	Very weak against
Treatment of postherpetic neuralgia: spinal cord stimulation	2 C+	Very low	Very weak
Treatment of postherpetic neuralgia: pulsed radiofrequency on intercostal nerve		Moderate	Moderate
Treatment of postherpetic neuralgia: pulsed radiofrequency adjacent to DRG		Very weak	Moderate
Treatment of postherpetic neuralgia: intrathecal administration of corticosteroid		Low	Strong against
Treatment of postherpetic neuralgia: lumbar sympathetic block		Very low	Very weak
Painful diabetic polyneuropathy			
Spinal cord stimulation	2 C+	Moderate	Moderate
Lumbar sympathetic block		Very low	Very weak
Meralgia paresthetica			
Infiltration of LFCB with local anesthetic with or without corticosteroid	2 C+	Very low	Very weak
Pulsed radiofrequency of LFCB	0	Very low	Very weak
Spinal cord stimulation	0	Not graded	Very weak
Carpal tunnel syndrome			
Intracarpal corticosteroid injection(s)	1 B+	Moderate	Moderate
Pulsed radiofrequency treatment of median nerve	0	Very low	Very weak
Phantom pain			
Pulsed radiofrequency treatment of the most tender part of the neuroma	0	Very low	Very weak
Spinal cord stimulation	0	Very low	Very weak
DRG stimulation		Very low	Very weak
Traumatic plexus lesion			
Spinal cord and DRG stimulation	0	Not graded	Very weak
Chronic refractory angina pectoris			
Spinal cord stimulation	2 B+	Low	Weak

*(Continued)*

Treatment	Recommendations in 2010†	GRADE Level of Evidence in 2015	Recommendations in 2018
Raynaud's phenomenon			
Radiofrequency of T2–T3 and T2 thermolesion with a local application of phenol	2 C+	Very low	Very weak
Spinal cord stimulation		Very low	Very weak
Ischemic pain of the extremities			
Sympathectomy	2 B+/-	Not graded	Very weak
Spinal cord stimulation	2 B+/-	High	Moderate
Chronic pancreatitis			
Plexus coeliacus block with local anesthetic and corticosteroid		Low	Weak against
Splanchnic nerve block	2 C+	Very low	Very weak
(radiofrequency)			
Spinal cord stimulation	2 C+	Very low	Very weak
Pain in patients with cancer			
Intrathecal drug administration	2 B+	Moderate	Weak
Epidural drug administration	2 C+	Very low	Very weak
Spinal cord stimulation		Very low	Very weak
Cervical percutaneous cordotomy	2 C+	Very low	Very weak
Neurolytic plexus coeliacus block	2 A+	High	Strong
Neurolytic plexus hypogastricus block	2 C+	Low	Weak
Intrathecal phenolization of lower sacral roots of cauda equina (lower end block)	0	Very low	Very weak
Kyphoplasty	2 B+	Not graded	Very weak
Vertebroplasty	2 B+	Very low	Very weak

\*2010 recommendations as reported in the previous guideline; the level of evidence in 2015 as identified by independent evaluation using GRADE; and the strength of recommendation as updated by the Guideline Committee in 2018, taking into consideration newer publications and potential risks for side effects and complications.

†A is the highest level of evidence (various RCTs of good quality), B stands for RCTs with methodological limitations or large observational studies and C stands for observational studies or case series.<sup>3</sup>

CRPS, chronic regional pain syndrome; DRG, dorsal root ganglion; GRADE, Grading of Recommendations Assessment, Development and Evaluation; HF-10, High frequency 10-kHz stimulation; LFCB, lateral femoral cutaneous nerve; SIJ, sacroiliac joint; TNF- $\alpha$ , tumor necrosis factor- $\alpha$ .

## Appendix

### Eligible Populations and Interventions

Population	Interventional treatments
Trigeminal neuralgia	Surgical microvascular decompression Stereotactic radiation therapy, gamma knife Percutaneous balloon microcompression Radiofrequency treatment of the Gasserian ganglion Pulsed RF treatment of the Gasserian ganglion
Cluster headache	RF treatment of the pterygopalatine ganglion (sphenopalatinum) Occipital nerve stimulation
Persistent idiopathic facial pain	Pulsed RF treatment of the ganglion pterygopalatinum (sphenopalatinum)
Cervical radicular pain	Interlaminar epidural corticosteroid administration Transforaminal epidural corticosteroid administration RF treatment adjacent to the cervical ganglion spinale (DRG) Pulsed RF treatment adjacent to the cervical ganglion spinale (DRG) Spinal cord stimulation
Cervical facet pain	Intra-articular injections Therapeutic (repetitive) cervical ramus medialis (medial branch) of the ramus dorsalis block (local anesthetic with or without corticosteroid)
Cervicogenic headache	RF treatment of the cervical ramus medialis (medial branch) of the ramus dorsalis Injection of nervus occipitalis major with corticosteroid + local anesthetic injection of atlanto-axial joint with corticosteroid + local anesthetic RF treatment of the cervical ramus medialis (medial branch) of the ramus dorsalis Pulsed RF treatment of the cervical ganglion spinale (DRG) (C2 to C3)
Whiplash-associated disorders	Botulinum toxin type A Intra-articular corticosteroid injection
Occipital neuralgia	RF treatment of the cervical ramus medialis (medial branch) of the ramus dorsalis Single infiltration of the nervi occipitales with local anesthetic and corticosteroids Pulsed RF treatment of the nervi occipitales Pulsed RF treatment of the cervical ganglion spinale (DRG) Subcutaneous stimulation of the nervi occipitales Botulinum toxin A injection
Thoracic pain	Intercostal block RF treatment of thoracic ganglion spinale (DRG) Pulsed RF treatment of thoracic ganglion spinale (DRG)
Lumbosacral radicular pain	Interlaminar epidural corticosteroid administration Transforaminal epidural corticosteroid administration in "contained herniation" Transforaminal epidural corticosteroid administration in "extruded herniation" RF lesioning adjacent to the lumbar ganglion spinale (DRG) Pulsed RF treatment adjacent to the lumbar ganglion spinale (DRG) Spinal cord stimulation (FBSS only) Adhesiolysis-epiduroscopy
Pain originating from the lumbar facet joints	Intra-articular corticosteroid injections RF treatment of the lumbar rami mediales (medial branches) of the dorsal ramus
Sacroiliac joint pain	Therapeutic intra-articular injections with corticosteroids and local anesthetic RF treatment of rami dorsales and rami laterales Pulsed RF treatment of rami dorsales and rami laterales Cooled/RF treatment of the rami laterales
Coccygodynia	Local injections corticosteroids/local anesthetic Intradiscal corticosteroid injections, ganglion impar block, RF ganglion impar, caudal block Neurostimulation
Discogenic low back pain	Intradiscal corticosteroid administration RF treatment of the discus intervertebralis Intradiscal electrothermal therapy Biacuplasty Disctrode
Complex regional pain syndrome	RF of the ramus communicans Intravenous regional block guanethidine Ganglion stellatum (stellate ganglion) block Lumbar sympathetic block Plexus brachialis block Epidural infusion analgesia Spinal cord stimulation Peripheral nerve stimulation
Herpes zoster and post-herpetic neuralgia	Interventional pain treatment of acute herpes zoster Epidural corticosteroid injections

**Appendix  
(Continued)**

Population	Interventional treatments
	Sympathetic nerve block
	One-time epidural corticosteroid injection
	Repeated paravertebral injections
	Sympathetic nerve block
	Epidural corticosteroid injections
	Sympathetic nerve block
	Intrathecal injection
	Spinal cord stimulation
Painful diabetic polyneuropathy	Spinal cord stimulation
Carpal tunnel syndrome	Local injections with corticosteroids
	Pulsed RF treatment median nerve
Meralgia parasthetica	Lateral femoral cutaneous nerve (LFCN) infiltration with local anesthetic ± corticosteroid
	Pulsed RF treatment of LFCN
	Spinal cord stimulation
Phantom pain	Pulsed RF treatment of the stump neuroma Pulsed RF treatment adjacent to the spinal ganglion (DRG)
	Spinal cord stimulation
Traumatic plexus lesion	Spinal cord stimulation
Pain in patients with cancer	Intrathecal medication delivery
	Epidural medication delivery
	Cervical cordotomy
	Neurolytic plexus coeliacus block
	Neurolytic nervus splanchnicus block
	Neurolytic plexus hypogastricus block
	Intrathecal phenolization of lower sacral roots of cauda equine
	Vertebroplasty
	Kyphoplasty
Chronic refractory angina pectoris	Spinal cord stimulation
Ischemic pain of the extremities and Raynaud's phenomenon	Sympathectomy
	Spinal cord stimulation
Pain in chronic pancreatitis	RF nervus splanchnicus block
	Spinal cord stimulation

DRG, dorsal root ganglion; FBSS, failed back surgery syndrome; RF, radiofrequency.

# Danke für Ihre Aufmerksamkeit

